

# PRIMARY SAPHENOUS VEIN INSUFFICIENCY

Prospective studies on diagnostic duplex ultrasonography and  
treatment with endovenous radiofrequency-resistive heating

*TERO  
RAUTIO*

Department of Surgery,  
University of Oulu

OULU 2002



***TERO RAUTIO***

**PRIMARY SAPHENOUS VEIN  
INSUFFICIENCY**

Prospective studies on diagnostic duplex  
ultrasonography and treatment with endovenous  
radiofrequency-resistive heating

Academic Dissertation to be presented with the assent of  
the Faculty of Medicine, University of Oulu, for public  
discussion in the Auditorium I of the University Hospital  
of Oulu, on June 7th, 2002, at 12 noon.

OULUN YLIOPISTO, OULU 2002

Copyright © 2002  
University of Oulu, 2002

Reviewed by  
Docent Tuija Ikonen  
Docent Jari Laurikka

ISBN 951-42-6723-0 (URL: <http://herkules.oulu.fi/isbn9514267230/>)

ALSO AVAILABLE IN PRINTED FORMAT  
Acta Univ. Oul. D 680, 2002  
ISBN 951-42-6722-2

ISSN 0355-3221 (URL: <http://herkules.oulu.fi/issn03553221/>)

OULU UNIVERSITY PRESS  
OULU 2002

# **Rautio, Tero, Primary saphenous vein insufficiency Prospective studies on diagnostic duplex ultrasonography and treatment with endovenous radiofrequency-resistive heating**

Department of Surgery, University of Oulu, P.O.Box 5000, FIN-90014 University of Oulu, Finland  
Oulu, Finland  
2002

## ***Abstract***

The purpose of the present research was (I-II) to evaluate the effects of clinical, hand-held Doppler (HHD) and duplex ultrasonographic examinations on the planning of operative procedure for primary varicose veins, (III) to assess the feasibility, safety and efficacy of endovenous saphenous vein obliteration with radiofrequency-resistive heating and (IV) to compare endovenous saphenous vein obliteration with conventional stripping operation in terms of short-term recovery and costs.

Sixty-two legs (in 49 consecutive patients) and 142 legs (in 111 consecutive patients) with primary uncomplicated varicose veins were examined clinically and with HHD and duplex ultrasonography for planning the subsequent treatment. At the saphenous-femoral junction (SFJ) and at the saphenous-popliteal junction (SPJ), sensitivity was 56-64% and 23%, specificity 93-97% and 96%, positive predictive value 97-98% and 43% and negative predictive value 44-45% and 91%, respectively. In 9% of the cases, the treatment plan was modified on the basis of the duplex ultrasound findings. The present study showed that, in primary uncomplicated varicose veins, the accuracy of HHD is unsatisfactory.

Thirty legs of 27 patients with varicose veins were treated using an endovenous catheter (Closure® System, VNUS Medical Technologies, Inc., Sunnyvale, CA), which was inserted under ultrasound guidance via a percutaneous puncture or a skin incision. The persistence of vein occlusion and complications potentially attributable to the endovenous treatment were assessed at 1-week, 6-week, 3-month, 6-month and 1-year follow-up visits. By the time of the last follow-up visit, occlusion of the treated segment of the LSV had been achieved in 22 (73.3%) legs. Persisting patency or recanalization of LSV was detected in 8 legs (26.7%). Postoperative complications included saphenous nerve paresthesia in 3 legs (10%) and thermal skin injury in one limb (3.3%).

Twenty-eight selected patients admitted for operative treatment of varicose veins in the tributaries of the primary long saphenous were randomly assigned to endovenous obliteration (n = 15) or stripping operation (n = 13). The patients were followed up for 7-8 weeks postoperatively and examined by duplex ultrasonography. The comparison of costs included both direct medical costs and costs due to lost of productivity. All operations were successful, and the complication rates were similar in the two groups. The sick leaves were significantly shorter in the endovenous obliteration group [6.5 (SD 3.3) vs. 15.6 (SD 6.0), 95 % CI 5.4 to 12.9,  $p < 0.001$ ,  $t$ -test]. When the value of the lost working days was included, the endovenous obliteration was societally cost-saving.

***Keywords:*** treatment, diagnosis, varicose veins, chronic venous disease, hand-held Doppler, duplex ultrasonography, endovenous, radiofrequency-resistive heating

*To Emma and Anna*

## Acknowledgements

This study was performed in the Department of Surgery in co-operation with the Department of Radiology, Oulu University Hospital, during the years 1997-2002. I would never have been able to accomplish this work without the help of a number of people, to whom I wish to express my deepest gratitude.

I am grateful to Professor Matti Kairaluoma, M.D., Ph.D., former Head of the Department of Surgery for giving me the opportunity to start this work.

The guidance of my supervisor, Professor Tatu Juvonen, M.D., Ph.D., present Head of the Department of Surgery, has been an example to follow. His thorough knowledge of research work, continuous support and never-failing optimism have been indispensable in helping this study to fruition. He has always found the time and patience for discussions on how to solve even my frequent minor problems.

I thank Jukka Perälä, M.D., Ph.D., with whom we spent numerous late hours to examining (or treating) women with varicose veins "just for science". During this study, I had an opportunity to follow the work of an excellent clinician, which made me think that even radiologists deserve respect. The reason for choosing varicose veins as the topic of study can be blamed on my other supervisor Docent Kari Haukipuro, M.D., Ph.D., who had confidence in my ideas and allowed "experimental" surgery in his Department. He also arranged financing for this work.

I thank the Docents Jari Laurikka, M.D., PhD, and Tuija Ikonen, M.D., PhD. for expert work as reviewers. Their constructive criticism and valuable comments had a major impact on the completion of this thesis.

An essential part of this work was done with my collaborators while working on the original publications. It was really a pleasure to work with my long-standing friend Heikki Wiik, M.D., who surprised me again with his diligence and multiple talents. The value of the contribution of Mr. Biostatistics, Pasi Ohtonen, M.Sc., cannot be underestimated. Without his guidance in the field of statistics, all this work would have collapsed in its initial stage. I was fortunate to become acquainted with hard-working Docent Fausto Biancari, M.D., Ph.D., who helped me a lot with the writing of the original publications and this dissertation. My roommate in Oulu University Hospital, Timo Heikkinen, M.D., Ph.D., shared with me his knowledge of the world of research. Pasi Karjalainen, M.D. provided insight into the design and management of standardised

anaesthesia. The cost analysis would not have been possible without the help of Professor Arto Ohinmaa, Ph.D., from the Department of Public Health Sciences, University of Alberta, Edmonton, Canada.

I thank Sirkka-Liisa Leinonen, Lic.Phil., for prompt and excellent language revision.

My thanks are due to my fellow surgeons at the Department of General and Gastroenterologic Surgery for sharing their clinical knowledge, for helping me by taking a greater share of the clinical work burden when I needed time for the study, and, most importantly, for their friendship. Mrs. Ritva Huhtala, the secretaries of the Department of Surgery, the staff of the Northern Radiological Division, the Surgical Outpatient Clinic and the Day Surgery Unit of Oulu University Hospital gave me unselfish and anxious assistance during this work.

Some honoured pensioned and still working senior surgeons in the Lapland Central Hospital took me by the hand during my first steps in varicose vein surgery. I had a great opportunity to follow the work of two brilliant senior surgeons, Erkki Forsström, M.D., and Risto Kauppinen, M.D. I am still at the beginning of my surgical learning curve compared to their skills.

I have been reloading my batteries during this work by clearing my brain capacity at least twice a year with a help of my Wenezian Brothers; Juha "Väly" Välimäki, M.D., Ph.D., Juha "Esso" Veijola, M.D., Jorma "Jomppe" Ryhänen, M.D., Ph.D., Pasi Kurtti, M.D., Juha "Kossu" Koskenkari, M.D., Pekka Kunelius, M.D., Ph.D. and Heikki "Heba" Wiik, M.D. The last of them and Heikki "The Voice" Takala, M.D. and "Mr. Sound", Auvo Hietaharju, have given me memorable moments and an irreplaceable opportunity to play R&B in the famous Cool Operator. My childhood friend Harri Ojala and fishing and hunting companion Janne Sillman have also supported me through these hard times.

I owe my very deep gratitude to my parents Siiri and Pentti Rautio for their love and support throughout my life.

All the other colleagues and friends and relatives are thanked for their endurance and charity, although I have not had enough time for them during the past years.

I thank my fiancé Ritva Koskela, M.D., for her understanding and love during the last months.

Finally, my thanks are due to my beloved daughters, Emma and Anna, who have been and still are my main reason to keep on going.

The study was supported by grants from the Oulu University Hospital, the Instrumentarium, and the VNUS Medical Technologies, Inc., Sunnyvale, CA.

Oulu, May 2002

Tero Rautio

## **Abbreviations**

CEAP	clinical, etiologic, anatomic and pathophysiologic classification of chronic venous disease
CVD	chronic venous disease
CVI	chronic venous insufficiency
CW	continuous wave
DVT	deep venous thrombosis
HHD	hand-held Doppler
LSV	long saphenous vein
MW	Mann-Whitney U-test
RF	radiofrequency
SFJ	saphenofemoral junction
SPJ	saphenopopliteal junction
SSV	short saphenous vein
TT	Student`s t-test
TV	tributary vein
US	ultrasound
VCSS	venous clinical severity score
VDS	venous disability score
VSDS	venous segmental disease score
VV	varicose veins

## **List of original publications**

This thesis is based on the following papers, referred to in the text by the Roman numerals I-IV.

- I Rautio T, Perälä J, Wiik H, Haukipuro K, Juvonen T (2002) Influence of preoperative duplex ultrasonography on the operative procedure for primary varicose vein surgery. *Phlebology* (in press)
- II Rautio T, Perälä J, Biancari F, Wiik H, Ohtonen P, Haukipuro K, Juvonen T Accuracy of hand-held Doppler in planning the operation for primary varicose veins (Submitted for publication)
- III Rautio T, Perälä J, Wiik H, Juvonen T, Haukipuro K (2002) Endovenous obliteration with radiofrequency-resistive heating for greater saphenous vein insufficiency. A feasibility study. *J Vasc Interv Radiology* (in press)
- IV Rautio T, Ohinmaa A, Perälä J, Ohtonen P, Heikkinen T, Wiik H, Karjalainen P, Haukipuro K, Juvonen T (2002) Endovenous obliteration versus conventional stripping operation in the treatment of primary varicose veins: a randomised controlled trial with comparison of the costs. *J Vasc Surg* (in press)



# Contents

Abstract	
Acknowledgements	
Abbreviations	
List of original publications	
1 Introduction.....	13
2 Review of literature.....	16
2.1 Surgical anatomy of the saphenous veins.....	16
2.2 Normal venous function.....	19
2.3 Pathophysiology of chronic venous disease.....	19
2.3.1 Uncomplicated chronic venous disease.....	19
2.3.2 Complicated chronic venous disease.....	20
2.4 Risk factors and etiology of chronic venous disease.....	21
2.5 Epidemiology of chronic venous disease.....	21
2.6 Classification of chronic venous disease.....	22
2.7 Diagnosis of chronic venous disease.....	25
2.7.1 Symptoms and signs.....	25
2.7.2 Clinical examination and tests.....	26
2.7.3 Hand-held Doppler.....	26
2.7.4 Duplex ultrasonography.....	28
2.7.5 Fluoroscopy examinations.....	29
2.7.6 Comparison of diagnostic methods.....	29
2.8 Conservative treatment.....	31
2.9 Operative treatment.....	32
2.9.1 Indications for surgery.....	32
2.9.2 Planning of the operation for primary saphenous vein insufficiency.....	33
2.9.3 Stripping operations.....	33
2.9.4 Local phlebectomies.....	35
2.9.5 Endovenous obliteration.....	35
2.9.6 Other treatment approaches.....	37
2.10 Outcome of operative treatment.....	37
2.10.1 Postoperative convalescence.....	37

2.10.2 Complications .....	38
2.10.3 Recurrence .....	39
3 Purpose of the present study .....	41
4 Patients and methods.....	42
4.1 Ethical aspects.....	42
4.2 Patients .....	42
4.3 Diagnostic methods and pathway (I-II).....	46
4.3.1 Hand-held Doppler (I-II).....	46
4.3.2 Duplex ultrasonography .....	46
4.3.3 Planning of treatment .....	48
4.4 Surgery .....	48
4.4.1 Anesthesia .....	48
4.4.2 Phlebectomy and sclerotherapy (III-IV).....	49
4.4.3 Stripping operation (IV).....	49
4.4.4 Endovenous obliteration (III-IV).....	49
4.4.4.1 Device description .....	49
4.4.4.2 Technique.....	51
4.5 Postoperative care and follow-up (III-IV) .....	52
4.6 Calculation of costs (IV) .....	53
4.7 Statistical analysis .....	54
5 Results.....	56
5.1 Diagnostic methods (I-II).....	56
5.1.1 Accuracy of hand-held Doppler (I-II) .....	58
5.1.2 Planning of the treatment of varicose veins (I-II).....	60
5.2 Feasibility of endovenous obliteration (III).....	61
5.3 Comparison of results after endovenous obliteration vs. stripping operation (IV) .....	61
5.3.1 Efficacy of endovenous obliteration and stripping operation and related complications .....	61
5.3.2 Sick leave and postoperative convalescence.....	62
5.3.3 Procedure-related costs .....	62
6 Discussion.....	64
6.1 Diagnostic methods (I-II).....	64
6.2 Planning of the treatment (I-II) .....	65
6.3 Feasibility of endovenous obliteration (III).....	66
6.4 Comparison of endovenous obliteration and stripping operation (IV) .....	67
7 Conclusions.....	66
8 References.....	66

# 1 Introduction

Diseases of the venous system are common among the Western population and result in considerable morbidity and costs to the health service. Half of the adult population has minor stigmata of venous disease (females, 50-55%; males, 40-50%) but less than half of them has visible varicose veins (females, 20-25%; males, 10-15%) (Callam 1994; Evans *et al.* 1994). The incidence of varicose veins (VV) increases with age. In Finland, the lifetime prevalence of VV is 18% among men and 32 % among women (Laurikka *et al.* 1993).

Chronic venous disease (CVD) is defined as abnormal functioning of the venous system caused by venous valvular incompetence, which may affect the superficial or deep venous system or both. The availability of noninvasive techniques that provide accurate diagnoses of conditions in the veins of the lower extremities has made it possible to specify functional and pathophysiologic conditions of the venous systems (Kistner *et al.* 1996). Limbs with CVD should be classified according to the CEAP system (Porter & Moneta 1995). The basis of this classification is that symptomatic limbs are assessed for clinical signs, etiologic problems, the anatomic distribution of the process and the pathophysiologic nature of the dysfunction. The seven categories of clinical classification are based on objective signs of CVD that are universally recognized (Kistner *et al.* 1996). As used in this book, the term 'varicose veins' (VV) refers to clinical class 2 of the CEAP classification. All patients examined or treated in this study had mild CVD with superficial venous system insufficiency.

The introduction of non-invasive methods for preoperative evaluation of varicose veins, such as hand-held Doppler (HHD) and duplex ultrasound has been associated with marked changes in the diagnosis and planning of treatment as compared with clinical assessment alone (Pleass & Holdsworth 1996). HHD is a relatively inexpensive method for assessing venous incompetence, and it is easily learned and performed by clinicians without any need for an experienced vascular technologist (Bladin & Royle 1987). However, this method is still inaccurate and, in a recent series, preoperative planning of treatment by HHD was associated with a 5-year recurrence rate of over 34% (Dwerryhouse *et al.* 1999). Currently, colour flow duplex scanning is considered the gold standard for non-invasive anatomical and functional assessment of venous reflux (Dixon 1996). Duplex ultrasound is particularly useful in the assessment of complex venous

disease and varicose vein recurrence (Jiang *et al.* 1999). However, duplex ultrasound examination is time-consuming and more expensive than HHD and requires an experienced examiner (van der Heijden & Bruyninckx 1993). A few studies have shown the superiority of duplex scanning over HHD (DePalma *et al.* 1993; van der Heijden & Bruyninckx 1993; Salaman *et al.* 1995; Campbell *et al.* 1997; Darke *et al.* 1997; Singh *et al.* 1997; Kent & Weston 1998a; Wills *et al.* 1998), but whether this superiority can be translated into significant changes in surgical planning and a better outcome is still not clear.

Interest in venous surgery has increased among vascular surgeons, in spite of this superficial vein procedures are still regarded by many as being part of general surgery (Galland & Magee 1998). In the Western countries, operations on mild CVD are among the commonest surgical procedures. In Finland, approximately 220 varicose vein operations per 100 000 inhabitants are performed each year (Laurikka *et al.* 1993). Conventional ablative surgery was described about hundred years ago (Mayo 1906). The stripping operation is a relatively inexpensive day surgery procedure that requires no special instrumentation.

Although superficial vein surgery is regarded as a safe and minor procedure, it is associated with significant surgical morbidity, patient dissatisfaction and a high late recurrence rate (Davies *et al.* 1995). However, it has been shown that the quality of life is reduced in patients with mild CVD as compared to the general population, and that surgery may improve it (Smith *et al.* 1999). Stripping operation has long-term advantages compared to high ligation of the saphenofemoral junction and multiple avulsions of the varicosities in the treatment of superficial vein insufficiency (Bergan 1996; Dwerryhouse *et al.* 1999).

Inadequate preoperative evaluation and incorrect planning of the surgical procedure are considered the main reasons for the high recurrence rates after superficial venous surgery. Recurrence is especially common after primary long saphenous vein (LSV) stripping operation. Rates of up to 40% at 5 years have been reported, and approximately 20% of varicose vein operations are done for recurrent varicosities (Negus 1993; Royle 1986). Furthermore, re-operations also result in marked losses of productivity. In Finland, the average duration of sick leave after a stripping operation has been four weeks (statistical information from the Finnish National Pensions Institution 1997). Therefore, the economic burden associated with primary mild CVD surgery and the treatment of recurrences is relevant.

This has led to the development of mini-invasive techniques to replace the traditional procedure of stripping the LSV. Endovenous obliteration (Closure® System, VNUS Medical Technologies, Inc., Sunnyvale, CA) is a new method, by which a catheter is inserted percutaneously to treat LSV insufficiency (Chandler *et al.* 2000a; Manfrini *et al.* 2000). Five Fr and 8 Fr catheters allow for obliteration of non-tortuous veins from 2 to 12 mm in diameter. The operative costs of this new technique are higher than those related to the conventional stripping procedure because of the costs of the device and the disposable catheters. On the other hand, the procedure is less invasive and may therefore result in shorter convalescence and an ability to resume work sooner, thus reducing the costs of lost productivity.

In the present clinical prospective studies, we evaluated the impact of ultrasound examinations on the preoperative diagnosis of primary varicose veins (I, II) and the

feasibility and efficacy of ultrasound (US)- and fluoroscopy-guided endovenous saphenous vein obliteration by radiofrequency-resistive heating in the treatment of primary venous insufficiency (III). We also compared the results of endovenous saphenous vein obliteration with conventional stripping operation in a randomized fashion in order to evaluate the outcome in terms of postoperative pain, length of sick leave, health-related quality of life and cost (IV).

## 2 Review of literature

### 2.1 Surgical anatomy of the saphenous veins

One of the pitfalls in venous surgery lies in inadequate knowledge of the venous physiology and anatomy. In contrast to the anatomy of the arteries, the venous anatomy is characterized by numerous variations, which have a certain impact on the diagnosis and surgery of CVD. The superficial venous system of the lower extremity is a network of fine veins, mainly from skin, that merge into branch veins running into two principal superficial veins, the long and the short saphenous veins (synonyms: greater or internal, and lesser or external, respectively). These two clearly identifiable systems are freely interconnected. It is generally believed that the term saphenous derives from the Greek word *safaina*, which means 'evident'. Historians have however, disproved this assumption as untenable. It seems that the origin of the word *saphenous* is the Arabic word *el safin*, which means 'hidden' or 'concealed'. This is in harmony with the deep location of the saphenous veins below the superficial fascia. (Caggiati & Bergan 2001)

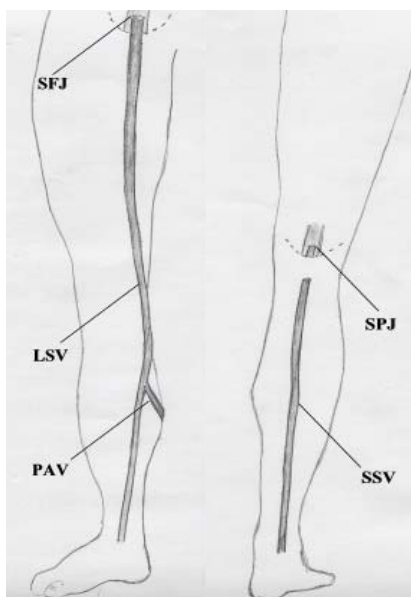
The superficial veins of the lower extremity are usually described as continuous single trunks. The long saphenous vein (LSV) runs subcutaneously up the inner leg and thigh to the groin and passes through the saphenous hiatus of the fascia lata to drain into the common femoral vein. The short saphenous vein (SSV) runs behind the lateral malleolus along the lateral side of the calf, passes through the deep fascia somewhere between the mid-calf and the knee and continues beneath the fascia to join the popliteal vein at a variable level, but usually opposite the femoral condyles. At the saphenopopliteal junction (SPJ), it commonly gives off an upward extension, called the Giacomini vein, which may run deep and parallel to the profunda femoris vein, or superficially, curving round to join the LSV via its posteromedial branch in the upper thigh. The superficial venous system of the lower limb is arranged as described in current textbooks in 50 % or less of patients (Shah *et al.* 1986; Kupinski *et al.* 1993). There is marked variation in the anatomy of the superficial venous system involving the origin, course, size, duplication and depth of truncal and tributary veins (TV), the number and topography of perforating veins, the valvular distribution and the arrangement of communicating veins.

A proper understanding of the anatomy of the superficial veins is elementary for improving the results of operative treatment for primary CVD (De Maeseneer *et al.*

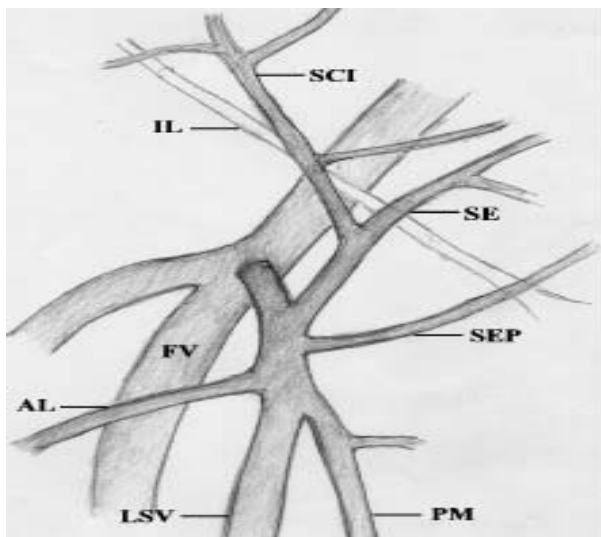
1995). From a surgical point of view, the most important variations occur at the venous junctions, the saphenofemoral junction (SFJ) in the groin and the saphenopopliteal junction (SPJ) in the popliteal fossa. The anatomical arrangement of the individual tributaries at the SFJ, namely the superficial epigastric, iliac circumflex and external pudendal veins as well as the lateral or medial accessory saphenous veins can be very different from one leg to another (Blomquist 1968). The anatomy of the SSV is even more complicated, because not only the tributaries may vary, but also the location of the saphenopopliteal junction. In only 50 to 70 % of the cases is the saphenopopliteal junction located in the popliteal fossa, whereas in about 10 % it is found below it. In the remaining 30% to 40 %, the SSV terminates clearly above the popliteal fossa, with or without connection with the popliteal vein (De Maeseneer *et al.* 1993). Duplication of the LSV is an anatomical variation, which is frequently reported in the surgical and radiological literature owing to its postulated role in recurrence after CVD surgery. The incidence of a double LSV system varies from 1 to 86 %. This large discrepancy in incidence may be due to the lack of a clear definition of a double LSV as well as to the lack of objective parameters for its identification (Ricci & Caggiati 1999). Large perforating veins (Hunterian, Dodd's and Boyd's perforators) of the LSV also have some influence on the pathogenesis of superficial venous insufficiency (Papadakis *et al.* 1989).

The fibular branch of the LSV posterior arch vein (Leonardo's vein) has connections with the posterior fibular vein via Cockett's perforating veins (Fig. 1). Neglected insufficiency in the posterior arch vein is quite often the cause of recurrence or even venous ulcer in the lower leg. The lateral subdermal system, or "Albanese" veins, arise from the infragenicular and paraperoneal veins, and are remnants of the fetal circulation (Albanese *et al.* 1969). They usually comprise an important component of lateral thigh and lateral calf teleangiectatic flares as the feeding conduit (Weiss & Weiss 1993b).

The anatomic relationships between the LSV and the saphenous nerve and the SSV and the sural nerve should also have an effect on the selection of the surgical technique in the treatment of the insufficient superficial veins. A cadaver study revealed an intimate relationship between the LSV and the saphenous nerve in the lower leg and the results indicated that the risk of nerve damage can be reduced by making the distal incision prior to extraction of the LSV immediately below the knee (Holme *et al.* 1988). The sural nerve descends anterolaterally to the SSV and gives off two lateral cutaneous calcaneal branches. This should be known when performing the surgical stripping of the SSV to avoid sural nerve damage (Simonetti *et al.* 1999).



**Fig. 1. Superficial veins: LSV; long saphenous vein, SSV; short saphenous vein, SFJ; saphenofemoral junction, PAV; posterior arch vein, SPJ; saphenopopliteal junction. (Picture drawn by Pentti Rautio)**



**Fig. 2. Anatomy of the right saphenofemoral junction: AL; anterolateral tributary, FV; femoral vein, IL; inguinal ligament, PM; posteromedial tributary, SCI; superficial circumflex iliac vein, SE; inferior superficial epigastric vein, SEP; superficial external pudendal vein. (Picture drawn by Pentti Rautio)**

## 2.2 Normal venous function

The primary and most obvious function of the venous system is to return to the heart the blood that has passed through of the arteries and capillaries. Four aspects of normal venous hemodynamics are of concern: venous pressure and the role of gravity, venous volume and its relationship with compliance, pressure-flow phenomena in collapsible tubes and venous valves and their contribution to the venous pump mechanism (Sumner & van Bemmelen 1997). By far the most powerful force propelling venous return flow is the musculo-venous pumping mechanism, which can handle large volumes rapidly and generate a force well in excess of that required for venous return against gravity (Scurr & Tibbs 1997). When the limb is in the dependent position, a normal set of valves in the deep and superficial veins will prevent reflux of blood against the normal direction of venous flow.

## 2.3 Pathophysiology of chronic venous disease

### 2.3.1 *Uncomplicated chronic venous disease*

Failure of competence in the venous valves will lead to retrograde flow down the limb when the patient stands up or after exercise movement has resulted in slack veins in the lower part of the leg. In the superficial veins, this is the basis of the most common venous disorder – simple varicose veins (Scurr & Tibbs 1997). The term 'varicose vein' refers to veins that are abnormally large and tortuous. This term applies to both the large protruding veins within the superficial subcutaneous fascia and the smaller "spider veins" that occur just beneath the epidermis (Goldman & Fronck 1989).

Varicose veins are classified according to the three circumstances of unnatural flow that result in enlarged tortuous veins. Primary varicose veins occur only in the superficial veins of the lower limb and are by far the most common variety of this disease. The pathogenesis of CVD is still largely unclear. Some authors believe that VV result from a failure of valves in the superficial veins, leading to venous reflux and vein dilatation (Goldman & Fronck 1989). Another theory suggests that the structural integrity of the vein wall is compromised, resulting in dilation of the vein and separation of valve cusps, which subsequently renders a previously competent valve incompetent (Cotton 1961). Secondary varicose veins are caused by an obstruction in the deep vein system of the lower limb, in which the superficial veins work as collateral vessels. Secondary venous insufficiency may sporadically also occur as a complication of an arteriovenous fistula.

In the case of teleangiectases, the dilatations develop between the epidermis and the hypodermis in the subpapillary dermal plexus and usually measure between 0.1 and 1 mm. They may be constituted by veins, arteries or capillaries. In chronic venous insufficiency, all teleangiectases are accompanied by reticular varices, even when not visible on a clinical examination. In most cases, the sources of reflux are distinguishable as incompetent perforating veins and situated beneath teleangiectatic efflorescences (Mariani *et al.* 2000).

Superficial venous insufficiency is most often caused by reflux via venous junctions or via perforating veins of the superficial veins to the LSV or SSV trunks. Less common sources of retrograde circuit are the ovarian veins via the pelvic veins or the pelvic veins to the upper thigh and the Giacomini branch or gastrocnemius vein via a mid-leg perforator to the calf. Until a few years ago, VV were considered to be a response to a dynamic process secondary to reversed flow and not merely a result of static distension of the veins. However, the suggestion that valvular insufficiency in the LSV or SSV is the principal cause underlying varicosities has now been questioned. Originally, it was thought that the descending valvular incompetence of veins commenced proximally and progressed distally. The results of duplex scanning studies have shown that reflux in the LSV is quite common without SFJ incompetence (Labropoulos *et al.* 1999; Hollingsworth *et al.* 2001), and the authors have suggested that the development of the primary VV may be an ascending rather than a descending phenomenon (Abu-Own *et al.* 1994).

In the CEAP clinical classification, objective signs of CVD are divided into seven categories with further subscripts to indicate the presence or absence of symptoms (Porter & Masuda 1995). Patients with uncomplicated CVD (teleangiectasies or varicose veins) are often asymptomatic. The relationship with mild clinical findings (CEAP clinical class 0-3) and leg symptoms is poor. Thus, surgery is unlikely to ameliorate symptoms in the majority of patients with VV. (Bradbury *et al.* 1999)

### ***2.3.2 Complicated chronic venous disease***

Venous insufficiency is a condition of inadequate venous return and hypertension when the patient is in an upright position. An increase in venous pressure results in a corresponding increase in capillary pressure and characteristic changes in the skin and subcutaneous tissue. Capillary transudation with protein molecules leads to deposition of fibrin, which forms a barrier to nutritional exchange between the capillaries and the surrounding tissue (Allegra & Carlizza 2000). Leukocytes are trapped in the capillaries causing further damage to the endothelium and the vessel walls and slowing down microvascular circulation (Dormandy & Thomas 1989). Extravasated hemosiderin gives the characteristic brown skin pigmentation. The outflow of fluid and corpuscles from the capillaries into the interstitial tissue initiates some of the mechanisms leading to symptoms of CVI (Allegra & Carlizza 2000). Swelling, venous eczema and dermatitis, lipodermatosclerosis, pigmentation and finally venous ulcer take many months, or even years, to develop. Sensory neuropathy is another feature of severe chronic venous insufficiency, and its distribution is coincident with trophic changes (Padberg Jr *et al.* 1999).

Skin changes ascribed to CVD may be caused by insufficiency of the deep or the superficial venous system or both. In patients with skin changes and ulceration, the incidence of reflux in the superficial veins has been found to vary from 17% to 53% (Sethia & Darke 1984; Hanrahan *et al.* 1991; Lees & Lambert 1993; Shami *et al.* 1993) In duplex scanning studies, reflux in the whole LSV occurs in approximately 8% of limbs with venous ulcer (Labropoulos *et al.* 1994a; Bello *et al.* 1999). However, Bello et al

observed deep venous obstruction in roughly two-thirds of such limbs (Bello *et al.* 1999). At any rate, the role of superficial venous insufficiency seems to be important in the development of venous skin changes.

The treatment of skin complications of CVD is expensive. Thus, the diagnostic evaluation and surgical treatment should be directed towards the subgroup of patients with complicated CVD in order to prevent leg ulcers (van den Oever *et al.* 1998).

## 2.4 Risk factors and etiology of chronic venous disease

The cause of primary VV is probably multifactorial. It has been suggested that a genetic or acquired predisposition may underlie the development of VV (Cornu-Thenard *et al.* 1994). Pregnancy has an association with the development of a variety of skin disorders including spider telangiectasias and VV (Sadick 1992). CVD occurs in 10% to 20% of pregnant women (Sumner 1981). The diameters of both competent and incompetent superficial veins increase during pregnancy and decrease during the postpartum period, gradually returning to their baseline values (Boivin *et al.* 2000). It has been suggested that hormonal or other systemic factors may play a significant role in the development of postpartum VV (Cordts & Gawley 1996). The results of recent epidemiological and biochemical studies support the theory of alternations in the sex hormone balance having a role in the pathogenesis of CVD even in menopausal women (Lee *et al.* 1999; Ciardullo *et al.* 2000). The increased concentrations of sex hormone receptors in the varicosed segments of veins reinforce the notion of hormonal involvement in the disease process (Mashiah *et al.* 1999).

The recommendations to use preventive compression stockings seem justifiable among employees exposed to a high workplace temperature and required to carry loads and stand for long periods (Sobaszek *et al.* 1998). It has been also suggested that the diet may have some role in CVD development, but the available literature does not allow firm conclusions about such an association (Adhikari *et al.* 2000). The degree to which each of these risk factors contributes to VV development is difficult to ascertain.

According to the results of Mini-Finland Health Survey, age, height, body mass index (BMI), standing at work and number of deliveries were found to be the risk factors associated with varicosities (Sisto *et al.* 1995). The Framingham study also showed that the higher risks for varicose veins have been associated with obesity, high systolic blood pressure, cigarette smoking and low levels of physical activity (Brand *et al.* 1988).

## 2.5 Epidemiology of chronic venous disease

The prevalence and incidence of CVD vary among different populations. VV is predominantly a condition encountered in Western societies, and its incidence increases with age (Evans *et al.* 1994). Venous disorders of the lower extremity are rare in African or Australian aboriginal populations, where their incidence range from 0 to 5% (Stanhope 1975; Richardson & Dixon 1977). The results of several clinical and questionnaire

studies suggest that varicosities are less common in non-Caucasian and underdeveloped countries than in Caucasian westernized societies, where the prevalence of lower-limb venous disease is high, as shown in Table 1 (Callam 1994). According to a recent article reviewing all papers on the epidemiological prevalence (1966-1999) of venous disease, increase with age is linear, suggesting a constant incidence and a cumulative prevalence (Adhikari *et al.* 2000).

*Table 1. Prevalence (%) of lower-limb venous disease in adults (Callam 1994)*

Signs of lower-limb venous disease	Men	Women
Venous disease (all types) <sup>1</sup>	40-50	50-55
Visible varicose veins <sup>2</sup>	10-15	20-25
Chronic venous insufficiency <sup>3</sup>	2-7	3-7
Chronic venous leg ulceration	0.5-1	1-1.5

<sup>1</sup>Any evidence of venous disease including venectasia; <sup>2</sup>reticular and truncal varicosities; <sup>3</sup>hyperpigmentation, eczema and liposclerosis

According to a questionnaire study whose methods were tested to be sufficiently reliable (Laurikka *et al.* 1995), VV were common in middle-aged Finnish people, among women. The results of the Mini-Finland study (Sisto *et al.* 1995) were comparable with the findings of another Finnish study (Laurikka *et al.* 1993) and studies from other western nationalities. The prevalence of VV as diagnosed by a physician was 25% in women and 7 % in men in Finland (Sisto *et al.* 1995).

The Edinburgh vein study (Evans *et al.* 1998; Evans *et al.* 1999) was the first relevant study on lower limb venous disease in the general population, using duplex scanning as a means of measuring venous reflux. Differing from the most of the clinical and questionnaire studies the age-adjusted prevalence of trunk varices was 39.7% in men and 32.2% in women. Hyphenweb and reticular varices each affected more than 80% of subjects (Evans *et al.* 1998; Evans *et al.* 1999).

There are only a few studies on the incidence of VV. In the Framingham study, the incidence of VV per year was 2.6 % in women and 1.9% in men, and the two-year incidence of VV was 39.4/1000 for men and 51.9/1000 for women (Brand *et al.* 1988).

## 2.6 Classification of chronic venous disease

VV are categorized as teleangiectases (blue to red), venulectases, reticular veins, and non-saphenous and saphenous VV, depending on their size and intradermal or subcutaneous location. Heyerdale and Stalker proposed the first anatomic classification in 1941 (Heyerdale & Stalker 1941). The 'revised vessel classification' suggested by Weiss and Weiss (Weiss & Weiss 1993a), based on the original classification by Duffy (Duffy 1988) and the system used by Widmer in the Basle study (Widmer & Wandeler 1978), are more advanced classifications, because they are more complete and categorize the vessels according to their size and appearance in an increasing order (Somjen 1995). However, these classifications do not take into account the tests of venous function and rely

exclusively on the clinical appearance. Sytchev (1985) described a more comprehensive staging approach based on hemodynamic and phlebographic data in combination with clinical findings (Sytchev 1985). The original presentation of Reporting Standards in Venous Disease of the Ad Hoc Committee described classifications by anatomic region, by clinical severity, by physical examination and by functional assessment (Porter *et al.* 1988)

None of these classifications achieved universal acceptance and widespread use. Because of this, there was no possibility for meaningful communication about chronic venous disease, and a basis for a more scientific analysis of management alternatives in VV was missing. An international Ad Hoc Committee of the American Venous Forum addressed these problems. They produced a consensus document for the classification and grading of chronic venous disease, the CEAP classification (Porter & Moneta 1995), which was formally endorsed by the American Venous Forum and by the Joint Council of the Society for Vascular Surgery and the North American-International Society for Cardiovascular Surgery. As shown in Table 2, limbs with chronic venous disease are classified according to clinical signs (C), cause (E), anatomic distribution (A), and pathophysiologic condition (P) (Porter & Moneta 1995). If the physician accepts that the anatomic and physiologic complexities of the venous system of the lower extremities are observable through physiologic and imaging techniques, correlations between disease states and treatment alternatives can be developed through the organized approach imposed by the CEAP system (Kistner *et al.* 1996). In the daily practice, the clinical classification is the most important and practical one (Table 3).

*Table 2. Classification of chronic lower extremity venous disease (Porter & Moneta 1995)*

Mark	Definition
C	Clinical signs (grade <sub>0,c</sub> ), supplemented by (s) for symptomatic and (a) for asymptomatic presentation
E	Etiologic Classification (Congenital, Primary, Secondary)
A	Anatomic Distribution (Superficial, Deep, or Perforator, alone or in combination)
P	Pathophysiologic Dysfunction (Reflux or Obstruction, alone or in combination)

Table 3. CEAP Clinical classification of chronic lower extremity venous disease (Porter & Moneta 1995).

Class	Clinical signs
0	No visible or palpable signs of venous disease
1	Teleangiectases, reticular veins, malleolar flare
2	Varicose veins
3	Edema without skin changes
4	Skin changes ascribed to venous disease (pigmentation, venous eczema, lipodermatosclerosis)
5	Skin changes (as defined above) in conjunction with healed ulceration
6	Skin changes (as defined above) in conjunction with active ulceration

During this study an American Venous Forum committee on venous outcomes assessment developed a venous severity scoring system based on the best usable elements of the CEAP system (Rutherford *et al.* 2000). We found the use of the Venous Clinical Severity Score (VCSS), the Venous Segmental Disease Score (VSDS) and the Venous Disability Score (VSD) easy and useful both in research and in the daily practice, when planning the treatment of primary VVs. These new scoring methods are meant to complement the current CEAP system (Rutherford *et al.* 2000). In the VCSS nine clinical characteristics of CVD are graded from 0 to 3 with specific criteria to avoid overlap or arbitrary scoring. Zero to three points are added for differences in background conservative therapy (compression and elevation) to produce a 30-point maximum flat scale (Table 4). VSDS combines the anatomic and pathophysiologic components of CEAP. Major venous segments are graded according to the presence of reflux and/or obstruction. It is entirely based on venous imaging, primarily duplex scan findings. This scoring scheme weights 11 venous segments for their relative importance when involved with reflux and/or obstruction, with a maximum score of 10. VDS is simply a modification of the existing CEAP disability score (Table 5).

Table 4. Venous Clinical Severity Score (VCSS)

Attribute	Absent = 0	Mild = 1	Moderate = 2	Severe = 3
Pain	None	Occasional	Daily	Limit activities
Varicose veins	None	Few, scattered	Multiple (LSV)	Extensive (LSV, SSV)
Venous edema	None	Evening, ankle	Afternoon, leg	Morning, leg
Pigmentation	None	Limited area	Wide (lower 1/3)	Wider (above 1/3)
Inflammation	None	Cellulitis	Cellulitis	Cellulitis
Induration	None	Focal (< 5 cm)	< lower 1/3	Entire lower 1/3
Number of AC	0	1	2	3
Duration of AC	None	< 3 months	3 months – 1 year	> 1 year
Size of AC	None	< 2 cm diameter	2-6 cm diameter	> 6 cm diameter
Comp therapy	Not used	Intermittent use	Most days	Continually

LSV, long saphenous vein; SSV, short saphenous vein; AC, active ulceration; lower 1/3, lower 1/3 of the leg.

Table 5. Venous Disability score (VDS)

Score	Definition
0	Asymptomatic
1	Symptomatic, but able to carry out usual activities* with-out compressive therapy
2	Able to carry out usual activities* only with compression and/or limb elevation
3	Unable to carry out usual activities* even with compression and/or limb elevation

\*Usual activities = patients activities before the onset of disability due to venous disease.

## 2.7 Diagnosis of chronic venous disease

### 2.7.1 Symptoms and signs

The clinical findings seen in patients willing to undergo treatments for primary CVD vary from the unesthetic appearance of teleangiectasies to venous leg ulcer. A thorough clinical history is of key importance when considering the indications for the treatment of CVD. A history of deep vein thrombosis (DVT), arterial occlusive disease, or diabetes should be sought. Insufficiency of superficial veins are commonly considered responsible for a wide range of lower limb symptoms, such as aching discomfort and heaviness on standing, premenstrual discomfort in the proximity of veins, swelling, pruritus, nocturnal cramps, restless legs, itching and tingling (Jones & Derodra 1997; Scurr & Tibbs 1997). The Edinburgh vein study (Bradbury *et al.* 1999) has shown that, in the general population, there is poor correlation between the presence of varicose veins detected on clinical examination and lower limb symptoms. The presence of reflux on duplex scanning also has a weak association with the symptoms (Bradbury *et al.* 1999; Bradbury *et al.* 2000). In the same study, furthermore, reflux was related to the presence of venous disease, but it was also present in subjects without VVs (Evans *et al.* 1998). This population survey

showed that only itching was significantly related to the presence of trunk varices in men, while women showed a significant relation between trunk varices and heaviness or tension, aching and itching (Bradbury *et al.* 1999). The authors of the Edinburgh vein study concluded that the level of agreement between the presence of symptoms and varicose veins is probably too low to be clinically useful (Bradbury *et al.* 1999).

Patients may also present with complications, such as superficial thrombophlebitis in varicose clusters and external bleeding from high-pressure venous blebs. The diagnosis of superficial thrombophlebitis, which is quite common, can usually be safely made on clinical grounds alone, if there are characteristic findings, such as a tender red swelling slightly warm to touch on the leg with an indurated cord of thrombosed vein. Although thrombosis of varicose veins typically runs a benign course, phlebitis of the saphenous system may propagate to the deep system or the saphenofemoral junction, which requires more aggressive therapy. Patients with superficial vein thrombosis may be prone to the development of DVT or saphenofemoral junction thrombophlebitis, and if hypercoagulability is present, they should be closely followed (Hanson *et al.* 1998). Untreated superficial saphenous vein insufficiency may induce lower leg skin changes, such as venous eczema, ankle hyperpigmentation, subcutaneous lipodermatosclerosis and venous ulceration (Bergan 1998). Several studies have shown that extensive deep venous reflux is not common, and superficial venous reflux is frequently present in limbs with complications (Mastroroberto *et al.* 1992; Lees & Lambert 1993; Neglen *et al.* 1993; Shami *et al.* 1993).

### ***2.7.2 Clinical examination and tests***

Patients should stand on a platform or steps, during the inspection of the legs for the distribution and size of varicose veins and possible venotensive skin changes. Clinicians should assess the likely pattern of insufficiency based on the clinical findings. SSV palpation has been shown to be a valuable part of the clinical examination (Aiono *et al.* 2001). However, the old belief that the insufficient perforating veins can be identified by palpation of the calf fascial defects has turned out to be false (Kim *et al.* 2000). Tests, such as the cough, tap, thrill, Brodie-Trendelenburg and Perthes' tests have been also shown to be inaccurate (McIrvine *et al.* 1984; DePalma *et al.* 1993; Singh *et al.* 1997; Kim *et al.* 2000). Because of this, the textbooks aimed at medical students and senior house officers should be revised in order to replace informations on these tests with instruction on how to use HHD and duplex ultrasonography in the examination of patients with CVD (Kim *et al.* 2000).

### ***2.7.3 Hand-held Doppler***

The use of Doppler ultrasound in the assessment of the venous system was first proposed mainly to detect venous occlusion. The first studies to describe the technique of directional flow detection for localizing venous valvular incompetency are from the early

70's (Folse 1970). Continuous wave (CW) Doppler was shown to be superior to clinical assessment alone in identifying the sites of deep to superficial incompetence (Chan *et al.* 1983; Hoare & Royle 1984; McIrvine *et al.* 1984; Mitchell & Darke 1987), and during the past decades, it has become an indispensable part of the routine clinical examination of patients with venous disease. The popularity of this examination has increased, obviously because it is inexpensive, requires minimal equipment, is quick and easy to perform on outpatient and only requires expertise that is commonly available (Blandin & Royle 1987; Kent & Weston 1998a).

In the HHD instrument, a piezoelectric crystal in the probe emits a continuous beam of ultrasound waves that detect erythrocytes moving within the targeted vein. The emitted sound wave reflects back to the receiving probe crystal at a changed frequency because of the motion of erythrocytes towards or away from the probe. The returned shifted frequency is converted into an amplified audible sound. Several Doppler probe frequencies (4.5 and 8 MHz) are commercially available for clinical use. The frequency of continuous-wave Doppler probes affects the depth from which useful information is obtained. In order to facilitate the passage of ultrasound between the probe and tissue, coupling gel is applied to the skin. Spontaneous flow signals are generally difficult to hear by Doppler ultrasound. Therefore, the vein or venous junction to be observed is located by anatomic landmarks and the tapping or squeezing test is used to promote venous flow, which results in an audible signal. The equipment used to indicate the direction of flow is useless during the examination of superficial veins. There are numerous ways to elicit reflux. The most common technique to assess the presence or absence of reflux is the release of calf compression with the patient in a standing position (Hoare & Royle 1984). An alternative method is to use the Valsalva manoeuvre, by which an increase in intrathoracic and intra-abdominal pressure induces reverse flow in an insufficient vein or venous junction. This has been suggested to be the most appropriate procedure to test venous valve function (Jeanneret *et al.* 1999), because it leads to a short and limited reflux when valves are competent (Masuda *et al.* 1994), but a pronounced and long-lasting reflux in the presence of valvular incompetence. There is not complete agreement about the reasonable reflux time, but it is quite common that an audible flow signal lasting longer than one second is used as a threshold for significant reflux (Campbell *et al.* 1997). It seems that the choice of probe frequency has no impact on the reliability of the HHD examination, even in obese patients (Kent & Weston 1998b).

HHD examinations have been made for years with good results in the diagnosis of primary CVD (Hoare & Royle 1984). However, after the introduction of duplex ultrasonography, several limitations of HHD in the evaluation of venous reflux in the lower leg have been recognized. In fact, HHD cannot insonate selectively an individual vessel, but it detects velocity from any artery or vein lying in the path of the ultrasonic beam. Because of the anatomical variability of the superficial and perforating veins of the lower leg, it is not surprising that HHD assessment is not sufficiently accurate. The method relies on "normal anatomy to successfully locate sites of reflux". (Wills *et al.* 1998). A bidirectional Doppler signal in the vicinity of a venous junction without any incompetent veins can be misinterpreted as venous reflux. A careful examination of veins not only in the vicinity of the junction, but also at some distance down the stem of the vein is important during CW Doppler assessment (Tong & Royle 1994). Because of these limitations, HHD is not an advisable method in the assessment of reflux in the popliteal

fossa, and its use is only indicated in the examination of SFJ and LSV as a screening test in patients with mild primary varicose vein disease (Nicolaidis 2000). The results of comparative studies on HHD and duplex ultrasonography will be discussed later in the Comparison of the Diagnostic Methods section.

#### ***2.7.4 Duplex ultrasonography***

Color flow duplex scanning is considered the gold standard for non-invasive anatomical and functional assessment of venous reflux (Dixon 1996). Its use has led to a better understanding of the pathophysiology of venous disease and improved the management of patients with venous disease (Coleridge Smith 1999). Duplex scanning combines echo pulsing with Doppler velocity recording. Colour units indicate the arterial and venous blood flow, which makes duplex evaluation faster and more accurate (Belcaro *et al.* 1993). Duplex ultrasound allows direct visualization of the veins and identification of blood flow through the venous valves. The anatomical information provided by duplex scans is useful both for the selection of treatment and as a guideline for surgery (Georgiev 1998).

Despite their widespread use in the evaluation of reflux disease, the methods of duplex examination have not been an object extensive research. There are numerous ways of elicit reflux, including the Valsalva manoeuvre (Masuda & Kistner 1992) or compression of the proximal or distal limb by either manual or pneumatic stimuli (van Bemmelen *et al.* 1989). Examinations may be conducted in various positions, such true supine, different degrees of reverse Trendelenburg or standing erect. According to the literature, the most commonly used technique is a pneumatic cuff system with the patient in a standing position. However, some authors have shown that the Valsalva manoeuvre with the patient in a semisupine position is a reliable method of duplex examination (Masuda *et al.* 1994). It has been suggested that the Valsalva manoeuvre should be standardized to improve the comparability of the results of different studies (Jeanneret *et al.* 1999). In most vascular laboratories, the examinations are usually performed by vascular technicians, but better results in duplex examinations are achieved when the surgeon does them personally (Georgiev 1998).

Duplex ultrasound examination is time-consuming and more expensive and requires experienced examiners compared to HHD (van der Heijden & Bruyninckx 1993). According to general consensus, duplex scanning should be used selectively in patients with suspected SPJ reflux or equivocal HHD findings and always in patients with venotensive skin changes, recurrent varicose veins or a history of DVT (Nicolaidis 2000). However, some authors believe that duplex examination is required before all operations for primary varicose veins, as this policy would probably result in a reduction of VV recurrence rates. Thus, the routine use of duplex scanning in the assessment of varicose veins may ultimately prove to be cost-effective. (Quigley *et al.* 1992; Singh *et al.* 1997; Mercer *et al.* 1998; Wills *et al.* 1998; Jutley *et al.* 2001)

### ***2.7.5 Fluoroscopy examinations***

The role of contrast venous studies has changed dramatically over the past decade due to the introduction of the noninvasive duplex scanning technique. Compared to descending phlebography, duplex ultrasound has been shown to be more sensitive in detecting both deep and superficial venous reflux below the knee. It also enables isolated segmental and short saphenous reflux to be studied, which is not possible with phlebography (Baker *et al.* 1993). Furthermore, the role of ascending phlebography is inferior in the preoperative assessment of varicose veins. Only patients with inconclusive color-coded duplex ultrasound results (e.g., complex variant venous anatomy) should be subjected to venography (Balducci *et al.* 1996). Phlebography is used primarily to study difficult problems in axial veins and perforators and to differentiate primary deep vein disease from postthrombotic deep vein disease. Dynamic ascending pedal phlebography is done on a tilting table with fluoroscopic and overhead film capacity. Spot films and videotape capabilities are helpful especially in the assessment of insufficiency in deep and perforating veins (Kistner & Kamida 1995).

In the case of superficial incompetence, technically simple varicography is of value in showing the source of incompetence, such as a short saphenous termination or a recurrent set of varicose veins of uncertain origin (Stonebridge *et al.* 1995). On the operating table, it facilitates the use of minimal incisions and precise surgery by serving as a “road map” to guide the surgeon (Hobbs 1980; Thomas & Bowles 1985; Hobbs 1986).

Selective ovarian and internal iliac phlebographies are used to investigate patients with lower limb VVs that fill from vulvar veins who are suspected to have incompetence of the ovarian veins with reflux into the vulvar veins via the internal iliac artery. In such patients, bilateral ovarian reflux is often associated with the pelvic congestion syndrome (Hobbs 1990).

There are a few reports about the use of three-dimensional non-contrast varicography by spiral computed tomography and contrast-enhanced magnetic resonance venography (Caggiati *et al.* 2001), which are not suitable for routine evaluation of varicose limbs nowadays, because of the high cost and the limited resources. However they may be useful in the evaluation of atypical varicosis.

### ***2.7.6 Comparison of diagnostic methods***

Table 6 summarizes the results of studies comparing the accuracies of HHD and duplex ultrasound in the evaluation of CVD (DePalma *et al.* 1993; van der Heijden & Bruyninckx 1993; Salaman *et al.* 1995; Campbell *et al.* 1996; Campbell *et al.* 1997; Darke *et al.* 1997; Singh *et al.* 1997; Kent & Weston 1998a; Mercer *et al.* 1998; Wills *et al.* 1998; Jutley *et al.* 2001). The specificity of the HHD examination varies from 71% to 100% in the SFJ and the LSV trunk and from 80% to 93% in the SPJ. According to the results of these studies the sensitivity in the same measurement points were 71-95% (SFJ) and 36-90% (SPJ). As shown in Table 6, the severity of CVD and the diagnostic techniques employed also differed in these studies. Because of this, it is not possible to consider their conclusions completely reliable.

Although most of these studies aiming to compare the rates of accuracy of HHD and duplex ultrasound proved the superiority of duplex scanning over HHD, the inclusion of patients with CVD other than the primary type represents a major pitfall and prevents any conclusive statement. Furthermore, several authors have reported their results of duplex scanning by employing different methods and positions of testing (van Bemmelen *et al.* 1989; Masuda & Kistner 1992). The conclusions in most of these studies have been based on the fact that HHD fails to determine the precise origin of reflux. In the case of LSV, insufficiency this is unlikely to influence the choice of surgical treatment. Only in four of these studies was the influence of HHD and duplex ultrasound observed in the preoperative assessment of CVD (van der Heijden & Bruyninckx 1993; Campbell *et al.* 1996; Singh *et al.* 1997; Wills *et al.* 1998). Therefore, although these studies have shown the superiority of duplex scanning over HHD, it is not clear whether this superiority can be translated into significant modifications of operative planning. Almost half of these authors have concluded that preoperative duplex ultrasound is necessary before all operations for primary varicose veins. But another half of the authors have suggested that HHD should be used as a screening test. They have also stated that duplex ultrasound should be performed selectively in patients with suspected reflux in the popliteal fossa or equivocal findings. This controversy suggested to us need to study the preoperative diagnostics of primary uncomplicated CVD.

Duplex ultrasound has displaced phlebography as a primary examination of lower limb venous disorders, because it has been shown to reflect the degree and distribution of venous reflux more accurately than descending venography or varicography (Neglen & Raju 1992; Phillips *et al.* 1995).

In contrast to duplex ultrasonography, which detects abnormalities in individual veins, volumetric diagnostic methods, such as ambulatory venous pressure measurements and plethysmographies, provides information derived from the entire leg. These methods are used mainly in the assessment of the effect on different therapies in research work. (Nicolaidis 2000)

Table 6. Studies comparing HHD and duplex ultrasonography

Author	Year	Patients and Methods					Specificity		Sensitivity		Concl
		n	VL	Pr	Test	Op	LSV	SSV	LSV	SSV	
van der Heijden	1993	48	yes	no	comp	yes	-	-	-	-	HHD
DePalma	1993	40	yes	no	vals	no	83%		48%		Duplex
Salaman	1995	42	yes	no	comp	no	94%	89%	92%	56%	HHD
Campbell	1996	201	yes	no	comp	yes	-	-	-	-	HHD
Darke	1997	73	yes	yes	comp	no	100%	93%	95%	90%	HHD
Campbell	1997	85	yes	yes	comp	no	-	-	-	-	HHD
Singh	1997	49	no	yes	comp	yes	-	-	-	-	Duplex
Kent	1998	72	no	no	comp	no	91%	80%	93%	82%	HHD
Wills	1998	188	yes	no	comp	yes	71%	92%	71%	36%	Duplex
Mercer	1998	61	yes	no	comp	no	-	-	73%	77%	Duplex
Jutley	2001	176	yes	yes	comp	no	-	-	-	-	Duplex

VL; vascular laboratory, Pr; only patients with primary VV, Test; reflux test, Comp; compression test, Vals; Valsalva manoeuvre, Op; operative planning, LSV; long saphenous vein, SSV; short saphenous vein, Concl; conclusion, HHD; hand-held Doppler as a screening test, Duplex; Duplex scanning as a primary investigation.

## 2.8 Conservative treatment

Most authors agree that compression therapy has a central role in the treatment of CVD. Compression therapy can be divided into elastic or non-elastic compression (Neumann 2000). Conservative treatment of patients with mild CVD is achieved most commonly by medical elastic compression stockings, which are manufactured with differing compression characteristics and in differing lengths, providing calf or calf and thigh compression. Gradient compression stockings alleviate the symptoms of venous insufficiency related to varicose veins. External compression augments the calf muscle pump, reduces edema and may also divert blood away from the distended veins, as decreasing lumen diameter of varicose veins minimizes the reverse flow within them (Weiss & Duffy 1999).

Class I stockings may be recommended over class II, since patient compliance is much higher and symptom improvement is identical (Jungbeck *et al.* 1997). Lightweight gradient compression hosiery is also very effective in improving symptoms of discomfort, swelling, fatigue, aching as well as leg tightness (Weiss & Duffy 1999). This also

supports the practice to recommend compression therapy to patients who are on the waiting list for surgical treatment. The beneficial effects of elastic stockings on venous hemodynamics are limited to the period when the stockings are worn. The benefits are completely abolished within a day after their removal (Labropoulos *et al.* 1994b). Patients with non-correctable venous insufficiency should be treated with lifetime compression therapy.

## **2.9 Operative treatment**

### ***2.9.1 Indications for surgery***

Varicose vein surgery is generally considered as a minor procedure. However, it may involve postoperative complications, and late recurrences are also relatively common. Therefore, the indications for operating patients with mild CVD should be adequately assessed. A large proportion of patients may want surgery for cosmetic reasons or due to anxiety that their disease may progress to chronic venous insufficiency and ulceration (Wolf & Brittenden 2001). A thorough clinical history and examination should be carried out before surgery. Although the level of agreement between the presence of symptoms and trunk varices is rather low (Bradbury *et al.* 1999), the presence of such symptoms as heaviness, aching or swelling and clinical or ultrasound evidence of saphenous vein reflux are generally accepted as indications for surgery. Obvious indications for surgery are skin changes ascribed to CVD, superficial thrombophlebitis and bleeding (Wolf & Brittenden 2001). According to the results of a survey on the current management of varicose veins by members of the British Vascular Surgical Society, the commonest indications for surgery are symptomatic and complicated varicose veins, although 55% of surgeons also perform surgery for cosmetic reasons (Lees *et al.* 1999).

Contraindications, such as arterial insufficiency, morbid obesity and diabetes, are only relative. Superficial veins acting as collaterals because of occluded deep veins should not be excised. It has been shown that operations for varicose veins in the legs of patients with lymphedema should be undertaken only if there is an absolute indication (ascending phlebitis or bleeding) (Foldi & Idiazabal 2000). An appropriate pre-operative anesthetic work-up should be performed based on the patient's age and co-morbidity. During the planning of treatment, it should be emphasized that varicose vein surgery is not curative, and that early surgery for uncomplicated veins will not prevent the development of new varicosities (Wolf & Brittenden 2001). Detailed informed consent should be obtained routinely (Lees *et al.* 1999). Because of the possibility of postoperative complications and the high recurrence rate, patients should be informed thoroughly about the operation for superficial venous insufficiency in order to prevent their dissatisfaction and any medico-legal action. In fact, in the UK, varicose vein surgery is the most common source of medico-legal action against general and vascular surgeons (Tennant & Ruckley 1996).

### **2.9.2 Planning of the operation for primary saphenous vein insufficiency**

Patients with varicose veins are frequently treated without any preoperative examinations often by young inexperienced surgeons (Scott *et al.* 1990). Inadequate preoperative evaluation and incorrect planning of the surgical procedure for primary varicose veins are considered the main reasons for the high recurrence rates. Careful preoperative assessment is required to identify points of reflux from the deep system into the superficial veins for surgery (Hoare & Royle 1984; Quigley *et al.* 1992). Despite the advances of noninvasive technologies, surgery for CVD is still based on clinical and fluoroscopic examinations (Campbell *et al.* 1996; Campbell *et al.* 1997). According to a British questionnaire study, only 65% of vascular surgeons used routinely HHD in the assessment of varicose veins and 10% used venography or varicography as a first-line investigation (Lees *et al.* 1999).

The difficulty of deciding which preoperative investigations to use in the assessment of venous insufficiency resulted in the development of a widely approved consensus document (Nicolaidis 2000), which presents a simple battery of appropriate tests to grade the diagnostic investigations into 3 levels and guides to the level of investigation in relation to the CEAP classes. This consensus document states that clinical and HHD examinations are sufficient enough in the case of class 0-2 primary CVD. Duplex should be used if reflux in the popliteal fossa is suspected or if there is a history of documented or possible DVT and in cases with venotensive skin changes (Nicolaidis 2000).

### **2.9.3 Stripping operations**

In Finland, conventional stripping operation remains the standard method of treating patients with superficial vein insufficiency, although new modifications of this operation and novel procedures have become more and more popular. The original method of saphenous vein stripping was described a hundred years ago (Mayo 1906), and the technical notes published by Rivlin in 1975 are still valid (Rivlin 1975).

However, there is some controversy as to whether or not to strip the LSV. There is a growing body of evidence to support the efficacy of limited LSV stripping from the groin to the knee level, which gives better long-term results than ligation of the SFJ alone (Sarin *et al.* 1992; Sarin *et al.* 1994; Bergan 1996; Dwerryhouse *et al.* 1999). Although the LSV stripping operation is the most effective treatment for primary insufficiency of venous junction and trunk, the most common cause of high recurrence rates is technically unsatisfactory initial surgery at the level of SFJ (Stonebridge *et al.* 1995). Therefore, it is important to recall some essential surgical details of SFJ ligation. The superficial tributaries of the LSV at the SFJ should be dissected and followed as long as possible back to the secondary branch points and then ligated and divided. Careful examination of the medial and lateral aspects of the femoral vein for 1-2 cm above and below the junction is one of the most reliable ways to ensure that all tributaries have been ligated and the anatomy has been correctly identified. This also ensures safe division of the LSV and ligation flush with the junction (Rivlin 1975). The lower end of the wound should be

retracted and the posterior-medial thigh vein identified and ligated before stripping (Wolf & Brittenden 2001). There is no convincing evidence that the use of a barrier membrane placed over the SFJ may prevent recurrence caused by neovascularization. Reports have described different techniques involving the use of silicone rubber implants or polytetrafluoroethylene patches. (Earnshaw *et al.* 1998; Glass 1998)

SPJ should be marked preoperatively, because of the complex venous anatomy in the popliteal fossa and variations in the level of SSV termination. Location of the SPJ can be made by duplex ultrasound or varicography (Hobbs 1980; Nicolaides 2000). Moreover, after operative treatment of SSV insufficiency, the most common cause of recurrence may be inadequate initial surgery (Tong & Royle 1996). SSV should be identified and dissected carefully up to the SPJ through a transverse incision.

The Giacomini and gastrocnemius veins may cause confusion if the anatomy of the popliteal fossa has not been properly exposed. Care should be taken to avoid damage to the common peroneal nerve (Lucertini *et al.* 1999). It should also be noted that stripping of the SSV is potentially associated with sural nerve injury (Simonetti *et al.* 1999). Short excision of the proximal SSV is thus recommended instead of stripping (Wolf & Brittenden 2001).

Until the last decade, the standard procedure for primary varicose veins was the stripping of the entire LSV trunk despite a lack of indicative evidence. In fact, duplex ultrasound studies have shown that, in cases with reflux in the SFJ, the distal part of the LSV is not always insufficient (Katsamouris *et al.* 1994; Labropoulos *et al.* 1994a). According to the results of a randomized Danish study (Holme *et al.* 1990), stripping of the lower part of the LSV may be downright harmful. Indeed, preservation of the distal LSV reduces the risk of nerve damage and retains enough vein for use should coronary artery or peripheral vascular bypass grafting be necessary in the future (Holme *et al.* 1990).

Traditionally, the removal of the LSV from the groin to below the knee has been done by employing a conventional flexible and disposable vein stripper plus olive. It is advisable to strip from above down as the reverse technique may cause the stripper to be passed inadvertently into the deep venous system (Wolf & Brittenden 2001). An alternative strategy of conventional stripping is the technique of inverting stripping originally described by Keller in 1905 (Keller 1905). About ten years ago, Oesch developed the 'PIN-stripping' (perforation-invagination) instrumentation and technique (Oesch 1993). It has been suggested to be minimally invasive and to result in a better cosmetic outcome with less damage to the tissues around the vein and less hematoma formation compared with standard stripping (Goren & Yellin 1994; Kent *et al.* 1999). According to two other randomized trials, however, the clinical benefits of PIN-stripping were not striking (Durkin *et al.* 1999; Lacroix *et al.* 1999). The LSV can also be removed by using the sequential avulsion technique, which has been shown to be less painful than stripping. It reduces bruising and avoids a significant scar below the knee (Khan *et al.* 1996).

An even more advanced technique has been used to minimize tissue trauma, nerve lesions and postoperative hematoma. The idea of a new endostripping procedure was developed from a technique of endoscopic LSV harvesting for coronary bypass surgery (Shamiyeh *et al.* 1999). This method utilizes subcutaneous CO<sub>2</sub> gas insufflation and

endoscopy and provides direct visualization to divide all tributaries of the LSV. This makes endostripping a virtually bloodless technique (Shamiyeh *et al.* 1999).

Adequate postoperative compression should be used to decrease the risk of subcutaneous hematoma formation (Travers *et al.* 1993). There are several possibilities to achieve this, but the choice of the compression dressing used for varicose vein surgery should depend primarily on the surgeon's personal preference as well as financial considerations (Bond *et al.* 1999). There is no benefit from wearing bandages or stockings for more than a week (Raraty *et al.* 1999). Surgeons should give unequivocal instructions to the patients concerning early mobilization.

#### ***2.9.4 Local phlebectomies***

Adequate treatment of superficial vein insufficiency and trunkal varicose veins should include the removal of varicosities. This can be easily accomplished by ambulatory stab avulsion phlebectomy, a technique introduced by the Swiss dermatologist Müller in 1966 (Ramelet 1991). Ambulatory phlebectomy consists of minimally invasive extraction of varicose veins through small incisions by hooks and clamps (Weiss & Weiss 1996; Ricci 1998). The phlebectomy probe can be helpful in releasing the periadventitial adhesions that tether varicose veins (Otley & Mensink 1999). However, several larger incisions along Cox's lines of skin cleavage will occasionally be required to remove large, long or densely adherent varicose veins.

The use of tourniquets during the superficial vein surgery allows easier and more complete avulsion of friable veins. Randomized trials on the use of tourniquets during VV surgery have shown a significant reduction in intraoperative blood loss and also improvement of the cosmetic outcome, as judged by independent observers and the patients themselves (Corbett & Jayakumar 1989; Thompson *et al.* 1990). The use of broad compression pads after ambulatory phlebectomy reduces hemorrhage and enhances blood resorption (Neumann *et al.* 1998).

Ambulatory phlebectomy is a safe technique with a low incidence of side effects. The most common complication is hematoma formation, while other complications, such as teleangiectasias, blister formation, phlebitis, hyperpigmentation, postoperative bleeding and nerve damage, are rare (Weiss & Weiss 1996; Neumann *et al.* 1998).

#### ***2.9.5 Endovenous obliteration***

The idea of using endovenous electro-surgical devices for venous wall collagen denaturation is not new. Over the past few decades, monopolar electro-surgical desiccation has been used sporadically (Politowski & Zelazny 1966; Watts 1972; O'Reilly 1977; O'Reilly 1981; Griffith *et al.* 1989; Gradman 1994). Endovenous obliteration with radiofrequency resistive heating is more advanced method, including precise heating, feedback controlled by the venous wall temperature and impedance (Manfrini *et al.* 2000; Chandler *et al.* 2000a).

Radiofrequency (RF) energy has been used in medical devices for decades. RF and microwave radiation are electromagnetic radiation in the frequency range 3 kHz to 300 GHz. A commercially available RF generator produces waveforms and supplies RF energy to the catheter electrodes in a bipolar mode at 460 kHz. High frequency current is used to generate heat, which induces denaturation of collagen. This is an irreversible rate-process wherein the native helical structure is transformed into a more random, coiled structure (Chen *et al.* 1998). Denaturation also results in an irreversible shrinkage of collagen, which is thereby a convenient metric of thermal damage. Experimental studies have showed that collagen tissue can be shortened precisely by the application of heat (Vangsness *et al.* 1997). The effectiveness of endovenous vein obliteration using RF energy (Closure<sup>®</sup> System, VNUS Medical Technologies Inc., Sunnyvale, CA) depends on carefully controlled heating up to a temperature sufficient to denature the venous wall collagen to an extent that will cause maximal lumen contraction without destroying the integrity of the vein (Chen *et al.* 1998).

There is one report about the procedure, where the intention was to reduce vein luminal diameter to eliminate vein reflux using controlled collagen-denaturation contraction (Manfrini *et al.* 2000). Technique was not efficient enough, and it has been abandoned. Instead the endovenous obliteration with RF resistive heating has turned out a feasible method for the treatment of superficial venous reflux. The two sizes of catheters allow for obliteration of veins from 2 to 12 mm in diameter and not too tortuous for catheter passage. The technique is minimally invasive, but still able to provide satisfactory immediate and long-term results (Chandler *et al.* 2000a; Manfrini *et al.* 2000).

The mid-term results of a multicentre feasibility study confirmed endovenous obliteration as potentially equally effective as the stripping operation in eliminating LSV reflux and in delaying the appearance of new varicose veins (Chandler *et al.* 2000a). However, the results of this study are not conclusive, since some study participants combined the endovascular technique with SFJ ligation (Chandler *et al.* 2000b). However, this large trial confirmed the feasibility of such a new technique, but pointed out a number of complications and recurrences. In part, this can be explained by the lack of experience with this technique. There are still numerous variations the techniques of inserting and localizing the catheter into the SFJ (Goldman 2000; Pichot *et al.* 2000).

The complications such as thrombophlebitis (6.7%), heat-induced paresthesia (19%), thermal skin injury (2.7%) and thrombus propagation (1.4%), were mainly related to spreading of thermal energy into tissues surrounding the vein (Manfrini *et al.* 2000). The occurrence of sural nerve paresthesias was so common (50%) that endovenous obliteration cannot be recommended for the treatment of SSV insufficiency. In five-month follow-up, 7.2% of the successfully treated veins were recanalized, probably because of technical errors (Chandler *et al.* 2000a). Simple procedural modifications have been shown to diminish the complications and treatment failure rates observed in feasibility studies (Goldman 2000; Pichot *et al.* 2000). The venous occlusion procedures can be performed under tumescent local anesthesia, the anesthetic solution being infiltrated along and around the entire length of the LSV and its tributaries (Goldman 2000). Subcutaneous saline solution should be infiltrated between the proximal LSV and the skin to avoid thermal skin injuries, if no local anesthesia is used (Chandler *et al.* 2000a).

Endovenous obliteration using the Closure® system is costly compared with traditional techniques, but enthusiastic proponents suggest that this technique enables early return to work, this being its major advantage. No long-term results are available, but in a world of consumer demand, it has been suggested that the technique may soon find its place. (Braithwaite 2001)

### ***2.9.6 Other treatment approaches***

A number of techniques including cryostripping (Etienne *et al.* 1997; Garde 1994), endovenous laser obliteration (Navarro *et al.* 2001), saphenous valvuloplasty (EV-SFJ and CHIVA) (Schanzer & Skladany 1994; Zamboni *et al.* 1998; Ik Kim *et al.* 1999; Incandela *et al.* 2000), angioscopic techniques (Hoshino *et al.* 1997), transposition of a competent tributary vein (Yamaki *et al.* 2001) and echo-sclerotherapy using a sclerosant foam (Cabrera *et al.* 2000; Tessari *et al.* 2001), have been proposed to minimize the trauma of CVD treatment or to spare the LSV for possible future artery bypass grafting. However, none of them have achieved widespread popularity. Larger clinical randomized trials with prolonged follow-up and cost analysis comparing these techniques with the stripping operation are needed before any of these new procedures can be considered the method of choice in the treatment of superficial vein insufficiency. The superiority of stripping operation over LSV sclerotherapy has been widely demonstrated (Jakobsen 1979; Neglen *et al.* 1993; Rutgers & Kitslaar 1994; Belcaro *et al.* 2000).

## **2.10 Outcome of operative treatment**

Patients are often disappointed about the outcome of surgery for primary uncomplicated CVD. One of reasons is that even in the presence of trunk varices, most of the lower limb symptoms are probably of non-venous origin (Bradbury *et al.* 1999). The patient's view of the outcome is mainly dependent on the cosmetic outcome. The surgeon's expertise is judged by the length and number of incisions, postoperative hematoma and pain (Shamiyeh *et al.* 1999). However, there is some evidence from the SF-36 health assessment studies that the postoperative quality of life is otherwise better among the patients who have undergone surgery for CVD (Baker *et al.* 1995; Smith *et al.* 1999). Another major cause of patient concern is the persistence or, more commonly, recurrence of varicosities.

### ***2.10.1 Postoperative convalescence***

Although operations on varicose veins are among the most common surgical procedures, there is not much adequate evidence-based information about convalescence after CVD surgery. No prospective studies have been published so far. In the past, varicose vein surgery was regarded as a safe procedure from the medico-legal standpoint. Actually,

stripping operations are associated with significant morbidity and patient dissatisfaction (Davies *et al.* 1995) and are a common source of litigation (Scurr 1990).

It has been stated that two or three weeks is a reasonable period of absence following a stripping operation, but it is not uncommon to see patients who remain off work much longer. There may be great variation in the length of sick leaves prescribed by the surgeon or general practitioner (Majeed *et al.* 1995). In Finland, the average sick leave after a stripping operation has been four weeks (information from the Statistics of the Finnish National Pensions Institution 1997). Mackay *et al.* (1995) have shown that only 38 % of patients claim to be symptom-free two weeks after surgery. The results of the same study also included the interesting information that 18.7% of patients needed some kind of treatment from their general practitioner during the first postoperative weeks.

### ***2.10.2 Complications***

The morbidity after surgical treatment of varicose veins is poorly documented in the surgical literature and is frequently underestimated (Miller *et al.* 1996). All surgeons operating patients with varicosities know that it is more a rule than an exception that there is subcutaneous hematoma formation in the thigh, causing morbidity after stripping operation. Pain, bruising and numbness are common two weeks postoperatively (Mackay *et al.* 1995).

Severe complications of conventional surgery for superficial vein insufficiency are rare, and there are only a few case reports about peri- or postoperative mortality. They are related to iatrogenic vascular injuries, and DVT and pulmonary embolism. According to a British retrospective review (Critchley *et al.* 1997), the overall incidence of major complications was 0.8% and most of them were DVTs. Comparable complication rates were reported in a large retrospective Swiss series, the incidence of pulmonary embolism among 1063 patients having been 0.56%, a rate similar to that reported after laparotomy (Huber *et al.* 1992). It is likely that such complication rates can be decreased by using adequate antithrombotic prophylaxis in high-risk patients (Campbell & Ridler 1995). Miller *et al.* (1996) reported an incidence of 0.1% of femoral vein injury among 997 consecutive patients. They concluded that the rate of such severe complications could be minimized with a good surgical technique and better supervision of surgical trainees. Also, the incidence of thromboembolic complications can be reduced by changing the policy of postoperative compression therapy. This incidence decreased from 0.7% to 0.2% in the series published by Miller *et al.* (1996).

The reported rate of wound infection, 4.0%-4.5%, is within the limits usually cited for clean surgery (Critchley *et al.* 1997; Mackay *et al.* 1995). Leakage of lymph may also occur after a stripping operation (Critchley *et al.* 1997).

Total stripping of the LSV is associated with a high incidence (39%) of saphenous nerve injury resulting in troublesome paresthesia or hyperesthesia in the affected leg. Partial stripping of the LSV reduces but does not eliminate the risk of damage to the saphenous nerve. The incidence of minor neurological complications after partial stripping operation varies from 4.2% to 7.0% (Negus 1986; Holme *et al.* 1990; Critchley

*et al.* 1997). The risk of more severe neurological complications is higher during SSV surgery (Lucertini *et al.* 1999).

### **2.10.3 Recurrence**

Recurrent varices after surgery are a common, complex and costly problem for both the patient and the health care system (Perrin *et al.* 2000). Recurrence, defined as the number of patients seeking further treatment after apparently adequate surgery, occurs in at least 20-30% of cases, increasing over time (Hobbs 1974; Sheppard 1978; Jakobsen 1979; Royle 1986). Therefore, the outcome of varicose vein surgery is often disappointing for the surgeon. This is why operation for CVD have been said to be the antithesis of glamorous surgery (Negus 1993).

The average time between the first and the second operations is usually long, ranging from 6 to 20 years.(Perrin *et al.* 2000) Approximately 20 % of varicose vein operations are performed for recurrent varicosities. Although this problem is so common, there are no reliable epidemiological data and no published socio-economic data specifically relating to recurrent varicose veins (Perrin *et al.* 2000).

The causes for such recurrences are variably discussed in the literature. The blame for recurrence has been previously laid on inadequate preoperative assessment and initial surgery involving a failure to perform complete SFJ ligation (Negus 1993; Lees *et al.* 1997). Despite the best intentions of surgeons to improve the accuracy of preoperative diagnostic methods and to perform well-targeted operations, the recurrence rate is still high. It has been both surprising and disappointing to discover that, even after correctly performed SFJ ligation, recurrent reflux across the former junction may develop and lead to recurrent superficial varicose veins (Jones *et al.* 1996; Dwerryhouse *et al.* 1999). A duplex ultrasound study showed that nearly half of the recurrences were attributable to inadequate surgical treatment at the initial operation or possible angiogenesis (Farrah & Shami 2001). According to two randomized trials, stripping reduced the risk of reoperation by two thirds as compared with mere flush ligation of the SFJ. However, 6% to 25% of patients experienced recurrent varicosities 2 to 5 years after stripping operation (Jones *et al.* 1996; Dwerryhouse *et al.* 1999).

After adequate surgery, new sites of reflux may appear due to neovascularization or disease progression (Glass 1988; Bradbury *et al.* 1994; Jones *et al.* 1996; Nyamekye *et al.* 1998; De Maeseneer *et al.* 1999). The development may become clinically significant within 6 months of surgery (Glass 1987a; Glass 1987b). Long-term 34-year follow-up has shown really depressing findings. According to a clinical duplex study, there was up to 60% incidence of junctional and circumjunctional reconnections after ligation of true SFJ and its related tributaries (Fischer *et al.* 2001). Research to find a way to prevent neovascularization after SFJ ligation, has so far failed to provide clear evidence of any benefit of a proposed modification of the surgical techniques (Earnshaw *et al.* 1998; Glass 1998).

Endovenous obliteration omits high ligation and leaves accessory tributaries of the SFJ, which can be regarded as a risk for recurrence (Neglen 2001). However, by performing endovenous obliteration without SFJ ligation, the normal venous drainage of

the lower abdominal and pudendal tissues can be preserved. This may reduce the stimulus to neovascularization (Chandler *et al.* 2000b). In view of the fact that angiogenesis is regarded as an important cause of recurrent reflux (Glass 1988; Jones *et al.* 1996; Nyamekye *et al.* 1998), endovenous obliteration may actually reduce the risk of recurrent varicosities. Long-term follow-up results in the future will help us to better evaluate whether the recurrence rate is reduced by the endovenous obliteration procedure.

The pattern of recurrence is highly variable and often involves multiple sites of incompetence (Jiang *et al.* 1999), which complicates the diagnostic assessment as well as the planning of redo surgery. It has been shown that nearly a third of recurrences originate at previously unoperated sites, confirming the need for objective venous assessment before repeated CVD surgery (Farrah & Shami 2001).

The consensus meeting on recurrent varicose veins after surgery (REVAS) published recommendations for the prevention of recurrence. Routine preoperative duplex 'mapping' is strongly recommended in order to avoid incomplete surgical treatment and to evaluate anatomical variations. Most authors emphasize the absolute necessity of performing complete SFJ or SPJ ligation and division. (Perrin *et al.* 2000)

### **3 Purpose of the present study**

The primary purpose of the present research work was to evaluate the impact of the diagnostic and treatment approach on primary saphenous vein insufficiency at Oulu University Hospital. Particular attention was given to the analysis of planning the treatment of primary uncomplicated CVD and the feasibility and clinical usefulness of a new procedure for long saphenous vein insufficiency. The objectives were:

1. to evaluate the impact of duplex ultrasonography on the treatment plan of patients with uncomplicated chronic venous disease (I)
2. to evaluate the effects of clinical judgement, hand-held Doppler and duplex ultrasonographic examinations on the planning of the operative procedure for primary chronic venous disease (II)
3. to assess the feasibility, safety and efficacy of ultrasound- and fluoroscopy-guided endovenous saphenous vein obliteration with radiofrequency-resistive heating in the treatment of primary venous insufficiency (III)
4. to compare a new method of endovenous saphenous vein obliteration with conventional stripping operation in terms of short-term recovery and costs (IV)

## **4 Patients and methods**

### **4.1 Ethical aspects**

The present studies were carried out at the Department of Surgery, Oulu University Hospital, during the years 1997-2001. All the study protocols were approved by the Ethical Committee of Oulu University Hospital, and the studies were run according to the provisions of the Declaration of Helsinki. All patients gave written informed consent before entry into the trials.

### **4.2 Patients**

The patients included in the studies I and II were consecutively and prospectively evaluated residents of the province of Ostrobothnia referred for surgery at the Department of Surgery, Oulu University Hospital. Patients scheduled for surgical treatment of primary, previously untreated and uncomplicated varicose veins were eligible for the studies. Previous history of deep venous thrombosis was an exclusion criterion. The characteristics of the patients included in the studies I and II are shown in Table 7.

*Table 7. Patients' characteristics (I and II).*

Clinical characteristics	Study I n= 49	Study II n= 111
Symptomatic limbs	62	142
Age (years)	45 (19-66)	42 (23-76)
Female/male	44/ 5	96 / 15
BMI	-	25.6 (18.3-52.8)
Venous disability score (no. of patients)		
0    No symptoms	5 (10 %)	14 (12 %)
1    Symptomatic, able to work without a support device	38 (78 %)	85 (77 %)
2    Able to work 8 hours/day only with a support device	6 (12 %)	12 (11 %)
3    Unable to work even with a support device	-	-

Figures are means in case not mentioned. BMI, body mass index.

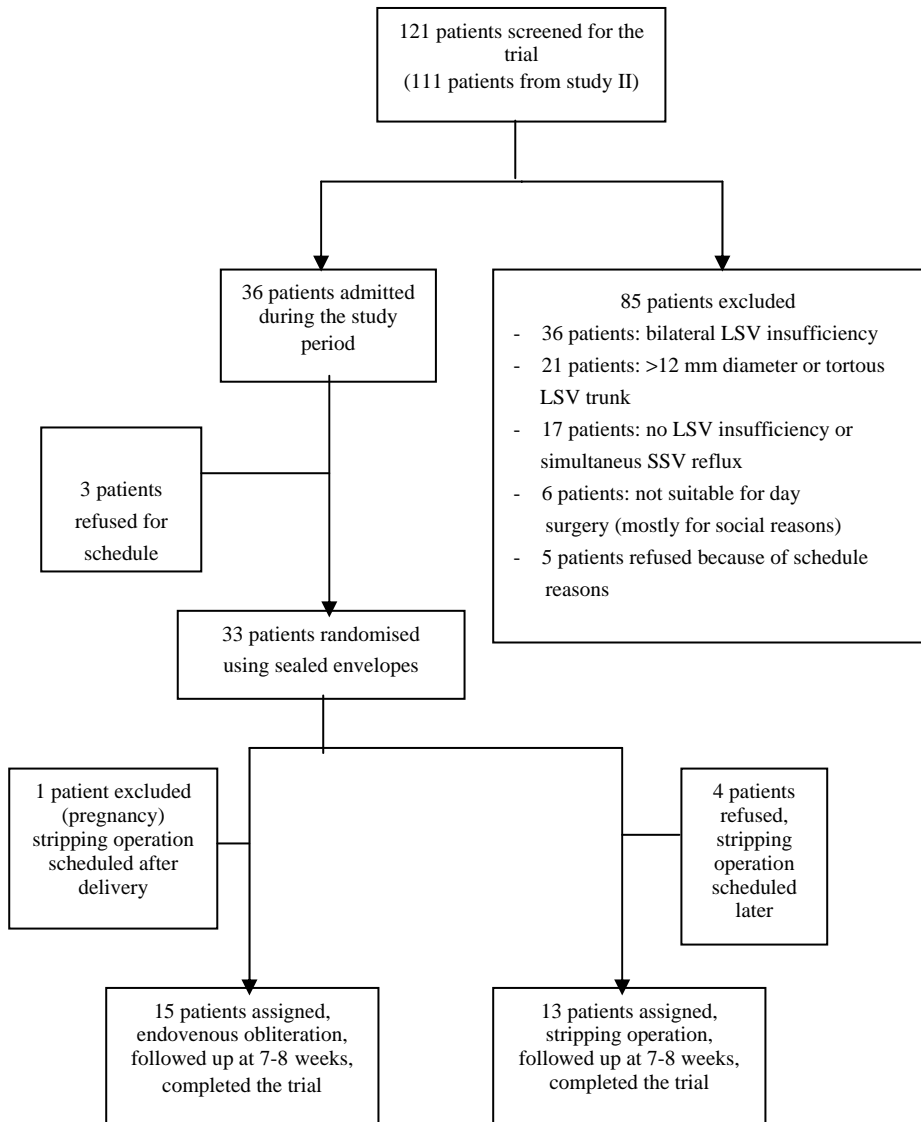
Out of the sixty-three screened patients (forty-nine patients from study I), twenty-seven with symptomatic lower extremity varicosities, edema, discomfort and pain were enrolled in study III. The inclusion criterion was symptomatic LSV reflux detectable by colour duplex ultrasound. Thirty-six patients were excluded, and the criteria for exclusion were heavily tortuous or large (>12 mm in diameter) long saphenous trunks. The study population consisted of 3 males and 24 females ranging in age from 24 to 58 years (median 37.5). Three patients had both legs treated.

For study IV, 121 consecutive patients (111 patients from study II) scheduled for surgical treatment of primary varicose veins at the Department of Surgery, Oulu University Hospital, were examined with colour duplex ultrasonography. Patients suitable for day surgery with symptomatic, previously untreated and uncomplicated LSV tributary varicosities and isolated unilateral saphenophemoral junction (SFJ) and LSV trunk insufficiency were eligible for the study. Patients with coagulopathy or multiple, tortuous and large-diameter (>12mm) LSV trunks were excluded. The patient characteristics and the trial profile are summarized in table 8 and in Figure 3. A more detailed description of the inclusion and exclusion criteria is given in the original publication.

*Table 8. Patient characteristics (IV)*

Clinical characteristics	Endovenous group (n = 15)	Stripping group (n = 13)
Age (years)	33 (SD 6.7)	38 (SD 6.8)
Female/male	14/1	12/1
BMI	23.3 (SD 5.3)	24.0 (SD 1.7)
Occupation (no. of patients)*		
Office work	7	6
Light physical work	7	6
Heavy physical work	1	-
Retired	-	1
CEAP classification (Median + range) *		
VCSS	5 (4-9)	4 (4-6)
VSDS	1 (constant)	1 (constant)
VDS	1 (1-2)	1 (constant)

Figures are means unless otherwise mentioned \*. LSV, long saphenous vein; CEAP, clinical, etiologic, anatomic and pathophysiologic classification of chronic venous disease; VCSS, venous clinical severity score; VSDS, venous segmental disease score; VSD, venous disability score.



**Fig. 3. Trial Profile (Study IV).**

### **4.3 Diagnostic methods and pathway (I-II)**

The examinations were performed at the outpatient clinic on the same day. In study II, a surgical registrar first performed a clinical examination and recorded her/his own opinion about the most appropriate diagnostic pathway and the type of treatment required. Thereafter, clinical and HHD examination was performed by a consultant general surgeon, and the same limbs were assessed with duplex scanning by a consulting vascular radiologist, who was blinded to the results of the HHD examination in the same way as in study I. The plan for subsequent treatment was recorded after these examinations. The clinical severity of varicose disease was classified according to the CEAP scoring method (Porter & Moneta 1995).

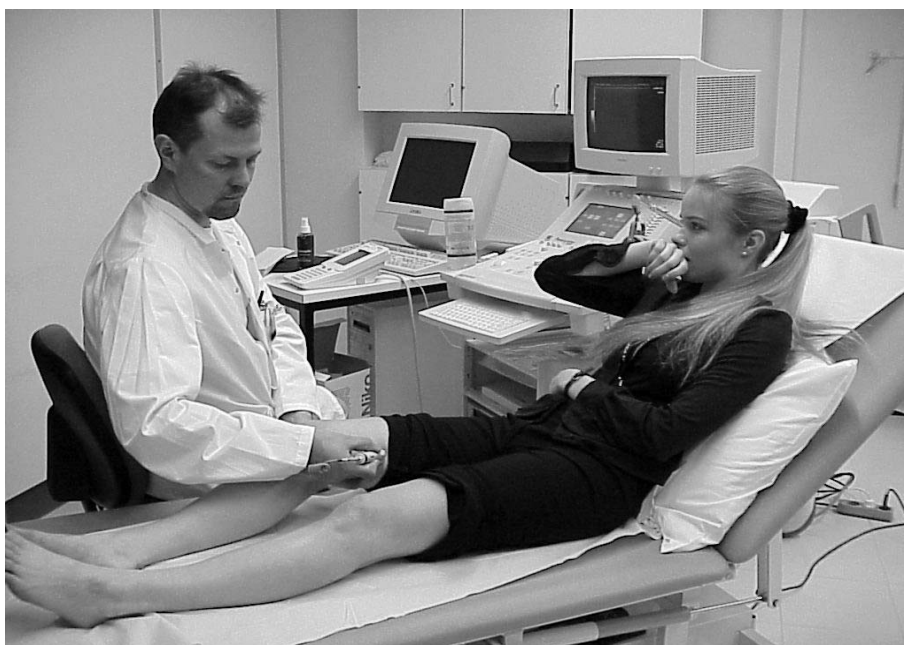
#### ***4.3.1 Hand-held Doppler (I-II)***

The hand-held Doppler assessment was performed using the standard technique with a 8 MHz probe (Hadeco mini-doppler ES-100X, Hayashi Denko CO. Ltd, Arima, Japan). The patients were in a semisupine position, and the reflux was demonstrated by a Valsalva manoeuvre. Tapping test was used to locate the venous junctions and the LSV trunk. The saphenofemoral junction (SFJ) and the LSV were insonated at three different points: at the upper thigh, at the lower thigh and at the calf in order to detect reverse blood flow. An audible flow signal lasting longer than one second was used as a threshold for significant reflux. In study I, the saphenopopliteal junction (SPJ) and the short saphenous vein (SSV) were examined only if reflux of the lesser saphenous vein was suspected based on the clinical findings or if there was no reflux in the LSV. Routine SPJ and SSV examinations were performed in the study II. Since HHD is known to be inaccurate in the evaluation of the popliteal fossa, caution was used in the interpretation of the findings in this region. Only obvious audible flow signals suspected to originate from the SPJ and the proximal LSV trunk were regarded as positive findings indicative of incompetence. The HHD examination of the popliteal fossa was performed in an upright position with calf compression and the threshold duration of reflux was one second.

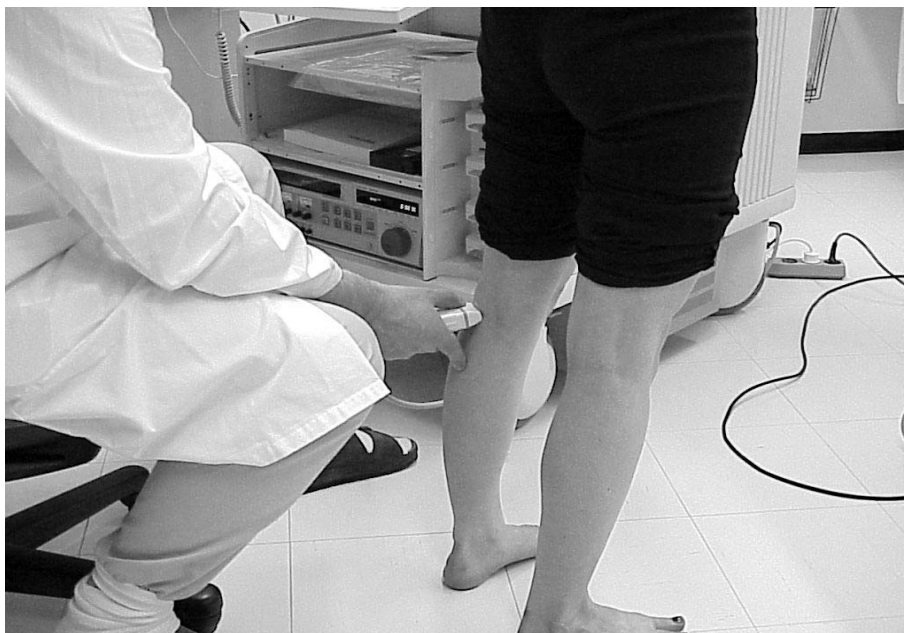#### ***4.3.2 Duplex ultrasonography***

On the same day, after the clinical and HHD examination, the patients were assessed with duplex scanning with a 7.5 MHz probe and venous flow settings (Toshiba Power Vision 8000, Japan). The patients were positioned supine with 45° truncal elevation, as during the HHD examination, and reflux was demonstrated by the Valsalva manoeuvre (Fig. 4). The entire length of the LSV was scanned to map the topographic anatomy of the vein. The duplex findings for reflux at different levels (see above) were recorded. Reverse flow of over one second was classified as pathological. The competence of SPJ was tested manually by squeezing and rapidly releasing the calf (Fig. 5). Reflux for over one second was judged as significant. The possible reflux of the femoral and popliteal veins was

detected as well. The anatomy of the popliteal fossa was examined with the patient in a standing position.



**Fig. 4. Duplex examination of the LSV trunk (photography by Auvo Hietaharju).**



**Fig. 5. Duplex examination of the popliteal fossa (photography by Auvo Hietaharju).**

### ***4.3.3 Planning of treatment***

The anatomical variations and reflux findings were analyzed jointly by the surgeon and the radiologist before the second (I) or third (II) plan for the treatment was made. In most cases, reflux at the superficial venous junction is an indication for ligation of the SFJ junction and a stripping operation. However, according to our practice, treatment plans are made individually based on the severity of the symptoms and signs of the venous disease. The same principles were followed in these studies. In our day surgery unit, sclerotherapy is used only for teleangiectasias. Stab avulsion with the hook technique is performed in case of varicosities without superficial vein insufficiency, most often for cosmetic reasons.

## **4.4 Surgery**

Study III was partially supported by a grant from VNUS Medical Technologies Inc. This pilot study made it possible to plan and implement the randomised study IV, which we did by means of independent funding. (We did not receive any financial support from any company.)

The endovenous obliterations were done by a surgeon in collaboration with a radiologist. The procedures on the patients enrolled in study III were performed in the fluoroscopy room at the Department of Radiology and the endovenous obliterations for study IV in the operating theatre of the day surgery unit. All stripping operations were also done by the same general surgeon with the same team and in the same operating theatre.

### ***4.4.1 Anesthesia***

In study III, the venous occlusion procedures were performed on outpatients under conscious sedation with intravenous propofol (Diprivan®, Zeneca Pharmaceuticals, Cheshire, England) controlled by an anesthesiologist and local anesthesia. The procedures in study IV were performed under standardized balanced general anesthesia (induction with alfentanil and propofol and maintenance with sevoflurane in O<sub>2</sub> and N<sub>2</sub>O) by maintaining the airway with a laryngeal mask and spontaneous breathing. The depth of perioperative anesthesia was monitored with the bispectral index (BIS index, Aspect Medical Systems INC., Natick, MA, USA) and sevoflurane-MAC (AS/3, Datex, Division of Instrumentarium Corp., Helsinki, Finland).

#### ***4.4.2 Phlebectomy and sclerotherapy (III-IV)***

Local phlebectomies were performed in all procedures. Multiple 1 to 2 mm incisions were made with a 18 G needle adjacent to previously marked side-branch varicose veins. An Oesch® hook (Salzmann Medico, St Gallen, Switzerland) was introduced into the subcutaneous tissue and advanced under the diseased vein segment, which was then captured by the hook and pulled out through the skin incision. The two ends of the exteriorized vein were then separated and divided between clamps. Each vein was removed individually by using a mosquito clamp to apply slow, steady traction. This was repeated as many times as necessary to remove the venous clusters. On an average, 10 separate stab incisions were required per extremity. Each incision was then closed with a Steri-Strip™ (3M Health Care, Borken, Germany). In case of teleangiectasias, we used microsclerotherapy with Aethoxysklerol® (5 mg/ml; Kreussler & CO. GMBH, Wiesbaden, Germany) or Glicerina® (Laboratorio Terapeutico M.R. s.r.l., Firenze, Italy) which were injected into superficial skin venules using a small 27 G needle. Compressive small wad pads were placed over the sclerotherapy areas. Elastic bandages were applied immediately after treatment and worn for one month postoperatively.

#### ***4.4.3 Stripping operation (IV)***

At the beginning of the stripping operation, the groin was dissected to fully expose the SFJ. The superficial tributaries of the LSV at the SFJ were dissected, and followed back to the secondary branch points and divided and ligated. The medial and lateral aspects of the femoral vein for 1-2 cm above and below were carefully examined before dividing the LSV. After the posterior-medial thigh vein had been identified and ligated, the LSV was stripped from just below the knee to the groin using the conventional flexible and disposable Venostrip® (Aesculap AG & CO, KG, Tuttlingen, Germany) with a 9 mm olive. The local phlebectomies were done and the compression stockings were put on before stripping the LSV, to diminish hematoma formation. The calf and groin incisions were sutured with 5/0 non-absorbable interrupted sutures.

#### ***4.4.4 Endovenous obliteration (III-IV)***


##### ***4.4.4.1 Device description***

The VNUS Closure® System (VNUS Medical Technologies. Inc., Sunnyvale, CA) comprises a computer-controlled, bipolar thermal energy generator (Fig. 6) and 5 Fr and 8 Fr catheters with sheathable electrodes (Fig. 7). The system induces fibrous obliteration of the vein wall by destroying the intima and by applying radiofrequency-resistive heating to accomplish contraction of the collagen of the venous wall. The heating is frequently monitored by a feedback system for vein wall temperature and impedance as well as for power consumption by the system. The two catheter sizes allow for

obliteration of veins 2 to 12 mm in diameter. Both catheters incorporate a central lumen for fluid infusion and the option of passage over a guide wire.



**Fig. 6. Radiofrequency energy generator (VNUS Closure®) (Picture modified from original article III published in Journal of Vascular and Interventional Radiology).**



**Fig. 7. Radiofrequency catheters (VNUS Closure®) The arrows indicate uninsulated microthermocouples. (Picture modified from original article III published in Journal of Vascular and Interventional Radiology).**

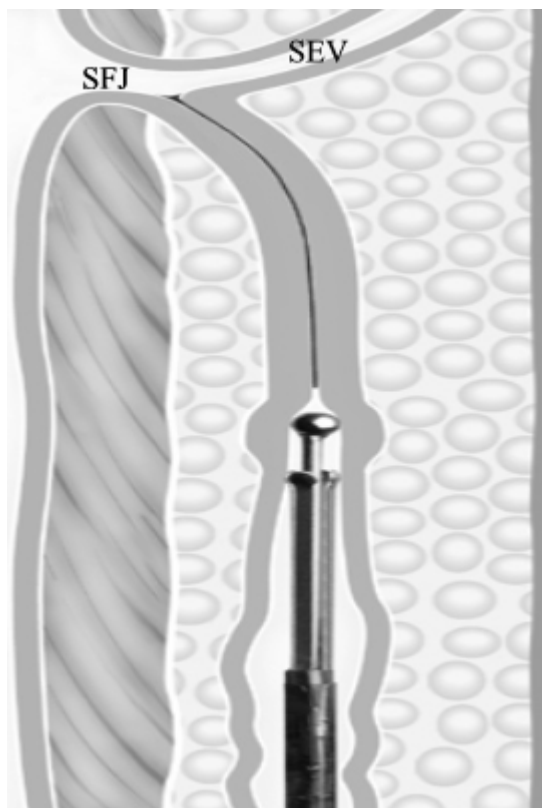
#### 4.4.4.2 *Technique*

The VNUS catheter was inserted percutaneously after local anesthesia at the puncture site with 10 ml of lidocaine (Lidocain®, Orion, Espoo, Finland) through a vascular sheath of 5 or 8 Fr, depending on the size of the catheter used. The 5 Fr catheter offers the advantage of insertion into veins as small as 2 mm in diameter, and the 8 Fr catheter is effective in treating intermediate range and larger veins, particularly those with larger (>3 mm) saphenofemoral junction (SFJ) tributaries. In practice, the choice of catheter size was made based on the maximum diameter of the LSV. If this diameter was 8 mm or more, an 8 Fr catheter was chosen. In the feasibility study (paper III), the sheath was inserted either through a percutaneous puncture under ultrasound guidance or through a small incision at the ankle, calf or groin. If there was a need for a skin incision at the medial calf for local phlebectomies to remove larger diameter varicosities, we also used this access to expose the LSV for the insertion of the catheter. We have used similar medial calf incisions as in conventional varicose vein operations for vein access of the stripping instrument. Otherwise percutaneous puncture was used and the alternative insertion sites were the groin, knee or ankle. In study III, the primary puncture site was the groin and the SFJ. The groin puncture was made on the most proximal part of the LSV no more than 1 cm below the SFJ. The catheter with sheathed electrodes was passed in an orthograde or retrograde fashion, depending on the puncture site. In some tortuous veins, a 0.014-inch guidewire (Seeker-14®, Boston Scientific, Fremont, CA) and fluoroscopic guidance (Neurostar®, Siemens, Germany) were used to pass the catheter through the tortuous segments and the valves. Ultrasound or fluoroscopic control was used to ensure proper positioning of the tip of the catheter in cases where the catheter was inserted from the knee or ankle level. The treatment of the LSV was planned to cover the vein up to the SFJ.

In study IV, we used a more standardized and more advanced technique. The catheters with sheathed electrodes were inserted percutaneously under ultrasound guidance into the LSV at the ankle level through a vascular sheath of 5 or 8 Fr in all cases. Subsequently, the catheter was passed up to the SFJ, and its correct position was controlled only by intraoperative ultrasound. Another technical difference compared to the feasibility study procedures was the routine use of subcutaneous saline solution infiltration between the proximal LSV and the skin.

In the studies III and IV, after the catheter had been inserted, the lower limb was elevated and an elastic compression wrap (Esmarck® bandage) was applied from the toes to the groin for exsanguination of the entire LSV. Supplemental manual compression on the groin region was used. The electrodes of the catheter were unsheathed and the wall contact of the electrodes was tested by measuring the impedance of the catheter. Heparinized saline (5000 IU Heparin / 11 saline) was infused through the central lumen to rinse the electrodes in order to avoid thrombus formation. The RF power level, the maximum temperature and the duration of treatment were selected using the control buttons on the front panel of the RF generator. After activation of the treatment circuit, the wall temperature was allowed to equilibrate at 85°C for 15 seconds. The catheter was then slowly (3 cm/min) withdrawn (Fig. 8) by keeping the temperature within 85° C ± 3°C, while the RF generator automatically controlled the impedance and RF power level.

The procedure was performed in a pullback manner, i.e. the treatment was started at the knee level when the groin was punctured and at the SFJ when vein access was made at the knee or ankle. Immediately after removal of the compression wrap, the treated segment was evaluated by colour Doppler ultrasound, to ensure proper occlusion of the vein. In this manner, it was possible to treat again the possibly unoccluded segment immediately.



**Fig. 8. Schematic view of endovenous obliteration with radiofrequency-resistive heating. SFJ, saphenofemoral junction; SEV, superficial epigastric vein.**

#### **4.5 Postoperative care and follow-up (III-IV)**

In the study III series, postoperative compression of the treated leg with elastic bandages was applied for three to four weeks. In the randomized trial, knee- and groin-length antiembolism stockings were applied immediately after the treatment and kept on for seven days. There were no limitations on mobilization, and the patients were encouraged to walk as soon as possible.

Clinical follow-up examinations in study III were carried out by the operating surgeon, and duplex scanning of the entire endovenously treated vein and the saphenofemoral junction were done by an experienced radiologist at 1 week, 6 week, 3 month, 6 month and 12 months. The patients' symptoms, new or recurrent varicosities, CEAP clinical class, and eventual complications were registered on each visit.

In study IV, the patients recorded their postoperative pain at rest, on standing and on walking using a visual analogue scale (VAS; range 0-10) on a daily basis during the first week and on the 14<sup>th</sup> postoperative day. The short-term RAND-36 generic health related quality of life questionnaire (validated for Finland) was used to measure health status before the procedure, and 1 and 4 weeks postoperatively. The patients were also asked to record the need and use of oral ibuprofen (the number of 600 mg tablets) or other analgesics. A sick leave was routinely prescribed for five days and continued over the phone for up to two weeks if necessary. If disability lasted for more than two weeks, the patient was scheduled for a control visit at the outpatient clinic.

The patients were re-examined after 7-8 weeks by color duplex ultrasonography. The postoperative CEAP scores were recorded. The patients were also asked if they were satisfied with the treatment and how long a sick leave they would have needed in their own opinion. The outcome measures were the duration of sick leave, pain, health related quality of life and satisfaction with the treatment.

#### **4.6 Calculation of costs (IV)**

For the cost analysis, which was made in co-operation with an expert of health care economics, the costs were divided into direct medical costs and indirect costs. The direct medical costs consisted of fixed and variable costs, as shown in Table 9. Indirect costs consisted of the value of lost productivity. Costs that could be assumed to be the same in both procedures (e.g. administrative, energy, overhead costs) were excluded. Operating times ("skin-to-skin") and operating room and recovery room times were measured in minutes and valued based on the average salary brackets and figures drawn from the hospital accounting system. Anesthesia and recovery room costs were estimated to be USD 72 (USD 1 = Euro 1.1) in both methods. Two specialists were involved in the endovenous procedure compared to one in the conventional alternative. The hourly salary of a specialist was USD 32. Investment costs included only the cost of the generator, and they were allocated to five years by using a 5% social discount rate. The basic instrumentation was the same in both operations. The specific costs of endovenous obliteration further included the price of the catheter and the rent of the ultrasound equipment. The other costs of day surgery were assumed to be the same. The postoperative costs included the additional follow-up visits and telephone consultations needed to lengthen sick leaves. The patients' medical costs were assumed to be the same, with the exception of the analgesics used during the first two weeks and the travel costs due to the follow-up visits. The units and the unit values of the cost factors as well as the sum totals are shown in Table 9. The indirect costs were calculated as costs caused by lost productivity due to a sick leave. The value of lost workdays was assessed based on the average wage level in Finland in the year 2000 (Statistics Finland 2000) plus 50% non-

wage costs for social security and other worker-based costs. A five-day working week was used in the calculation of indirect costs.

*Table 9. Costs of endovenous obliteration and conventional surgery in the treatment of primary varicose veins (USD\*) (IV).*

Costs	Conventional operation		Endovenous obliteration	
	Units and unit price	Total	Units and unit price	Total
<b>Fixed costs</b>				
Generator	0	0	1, à \$ 14.540	14.540
Annual cost (5% discount rate)		0		3.360
<b>Variable costs</b>				
Surgeon's salary	99 min, à \$ 32	53	115 min, à \$ 32	61
Radiologist's salary	0	0	75 min, à \$ 32	40
Operating room time	99 min, à \$ 73	121	115 min, à \$ 73	140
Anesthesia and recovery room	1, à \$ 72	72	1, à \$ 72	72
Basic instrumentation	1, à \$ 50	50	1, à \$ 50	50
Closure catheter	0	0	1, à \$ 446	446
US equipment rent	0	0	1, à \$ 31	31
<b>Postoperative costs</b>				
Additional follow-up	6/13 patients, à \$ 62	29	1/15 patients, à \$ 62	4
Sick leave by telephone	13/13 patients, à \$ 28	28	33 %, à \$ 28	9
Travel to follow-up visit	6/13 patients, à \$ 8	4	1/15 patients, à \$ 8	1
Analgesic medication	1.3 tbl. 14 days, à \$ 0.3	6	0.4 tbl. 14 days, à \$ 0.3	2
Total variable costs		360		794
<b>Indirect costs</b>				
Lost working days (LWD)	11.6 LWD, à \$ 135	1.566	4.5 LWD, à \$ 135	607

\*1 USD = 1.1 Euro (May 2001)

## 4.7 Statistical analysis

The statistical analysis and design of the studies II and IV were made in co-operation with an expert of biostatistics. The summary statistics for continuous variables were expressed as means with standard deviation (SD) or as medians with interquartile range (IQR, 25<sup>th</sup> and 75<sup>th</sup> percentiles). Exact 95% confidence intervals (95% CI) were calculated for sensitivity and specificity, for positive and negative predictive values and for accuracy.

Sensitivity: Probability that the diagnostic test result will be positive when the disease is present

$$= \frac{\textit{All testing positive and diseased}}{\textit{All diseased}}$$

Specificity: Probability that the diagnostic test result will be negative when the disease is not present

$$= \frac{\textit{All testing negative and non diseased}}{\textit{All non - diseased}}$$

Positive predictive value: Probability that the disease is present given that the test result is positive

$$= \frac{\textit{All testing positive and diseased}}{\textit{All testing positive}}$$

Negative predictive value: Probability that the disease is absent given that the test result is negative

$$= \frac{\textit{All testing negative and non - diseased}}{\textit{All testing negative}}$$

Accuracy: Probability that the test result is correct (positive when present, negative when absent)

$$= \frac{\textit{Total correct results}}{\textit{Total number of tests}}$$

Point estimates and confidence intervals were calculated using the CIA-software version 2.0 (Confidence Interval Analysis).

The serial measurements were summarised by calculating the average score over the study period for each patient. The change from the baseline health related quality of life scores to those recorded at 1 week and 4 weeks postoperatively was determined and the other inter-group comparisons were made by Student's *t*-test (TT) or the Mann-Whitney U-test (MW) as appropriate. The categorical values were analyzed by the chi-square (CHI) or Fisher's exact test (F). Kendall's rank correlation coefficient ( ) and coefficient of determination ( $\tau^2$ ) were calculated. (IV)

Sensitivity analysis was done to estimate the effects of the changes in the main background variables. The influence of indirect costs was tested using 50% of the estimated costs. The influence of retired patients on indirect costs was tested by assuming that 25% or 40% of the patients were retired. The scenario with one specialist performing the whole operation and no discounting of investment costs was also analyzed. Two-way sensitivity analysis was done, assuming that one specialist performed the operation and the indirect costs accounted for 50%, 60% or 75% of the estimated costs.

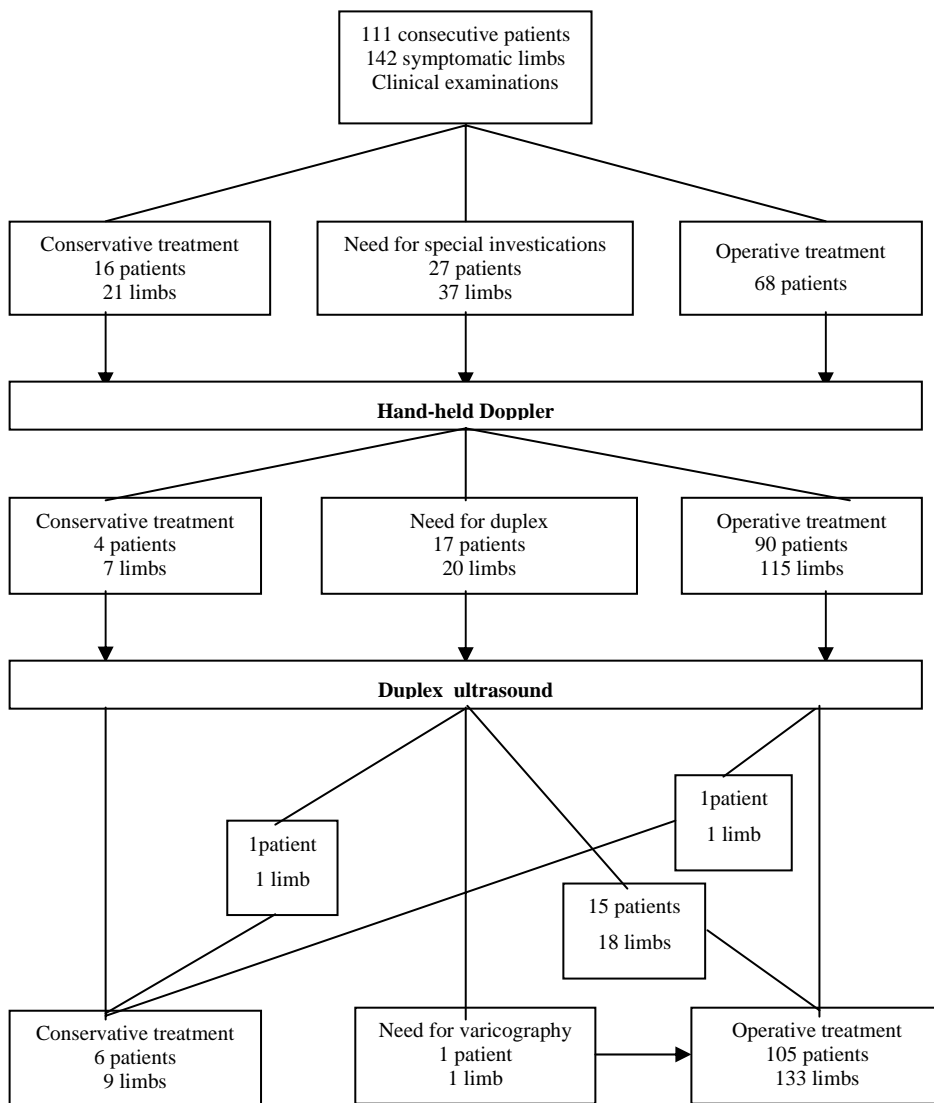
In all studies, the statistical analyses were performed by using the SPSS 10.0 software (Statistical Package for the Social Sciences; SPSS, Chicago, Ill).

## **5 Results**

### **5.1 Diagnostic methods (I-II)**

Superficial vein (LSV or SSV) reflux was detected by duplex scanning in 55 (89%) limbs (95 % LSV and 5 % SSV) in study I and in 116 (82%) limbs (90 % LSV and 10 % SSV) in study II, where reflux in the superficial vein tributaries without insufficiency of the main saphenous veins was observed in 22 (16%) limbs. Duplex ultrasonography showed no superficial truncal venous reflux without insufficiency of the venous junction or synchronous SFJ and SPJ reflux. In the remaining limbs (11% in study I and 3 % in study II) no reflux could be demonstrated. The deep veins were competent in all cases but one in study II. No duplex findings showing insufficiency of the lower limb perforating veins were seen.

The patients and the symptomatic limbs (paper II) were divided into 3 groups according to the plans made by the surgical registrar on the basis of the clinical examinations. The diagnostic pathway of study II is shown summarized in Figure 9.



**Fig. 9. Diagnostic pathway (study II).**

### ***5.1.1 Accuracy of hand-held Doppler (I-II)***

A comparison of the results of HHD assessment and duplex scanning is shown in Table 10. On the basis of the clinical examination, SPJ reflux was suspected in two limbs in study I.

Table 10. Comparison of the findings of hand-held Doppler examination and duplex scanning (I).

Hand-held Doppler	Reflux on Duplex		No reflux on Duplex	
	Reflux detected	No reflux detected	Reflux detected	No reflux detected
Study I (n= 62)				
SFJ	31	17	1	13
LSV 1	24	25	1	12
LSV 2	22	19	3	18
LSV 3	15	17	3	27
Study II				
SFJ (n = 142)	59	46	1	36
LSV 1 (n = 142)	54	39	8	41
LSV 2 (n = 142)	53	33	10	59
LSV 3 (n = 142)	46	23	14	59
SPJ (n = 112)*	3	10	4	95

Values are the number of legs. SFJ: saphenofemoral junction; LSV: long saphenous vein; LSV1: upper thigh; LSV2: lower thigh; LSV3: calf; SPJ: saphenopopliteal junction. \*Thirty legs were excluded from this analysis because of uncertain HHD findings in the popliteal fossa.

The sensitivity, specificity and positive and negative predictive values of the HHD technique at the SFJ and at the three different measurement points on the LSV trunk are shown in Table 11. In study II, the findings at the SPJ were also evaluated, and sensitivity was 23 % (8-50) and specificity 96 % (90-98). However, these findings were calculated after exclusion of 30 indifferent HHD findings.

*Table 11. Accuracy of the hand-held Doppler in detecting saphenous vein reflux at different sites in 142 limbs (Studies I and II).*

Tests diagnostics	SFJ		LSV 1		LSV 2		LSV 3	
	Study I (n=62)	Study II (n=142)	Study I (n=62)	Study II (n=142)	Study I (n=62)	Study II (n=142)	Study I (n=62)	Study II (n=142)
Sens	64 (50-76)	56 (47-65)	49 (36-63)	58 (48-68)	54 (39-68)	62 (51-71)	47 (30-64)	67 (55-77)
Spec	93 (70-99)	97 (86-100)	92 (67-99)	84 (71-92)	86 (65-95)	82 (70-90)	90 (74-97)	81 (70-88)
PPV	97 (84-99)	98 (91-100)	96 (81-99)	87 (77-93)	88 (70-96)	84 (73-91)	83 (61-94)	77 (65-86)
NPV	45 (29-62)	44 (34-55)	32 (20-49)	51 (41-62)	47 (33-64)	58 (47-69)	61 (47-74)	72 (61-81)

Values are percentages (95% CI); SFJ: saphenofemoral junction; LSV: long saphenous vein; LSV1: at the upper thigh; LSV2: at the lower thigh; LSV3: at the calf; Sens: sensitivity; Spec: specificity; PPV: positive predictive value; NPV: negative predictive value.

### ***5.1.2 Planning of the treatment of varicose veins (I-II)***

The treatment plan based on clinical and HHD examinations was modified after duplex scanning in the case of six limbs (9.7%) in study I and thirteen limbs (9%) in study II. Both inappropriate (five limbs in the study I and four limbs in the study II) and inadequate (one limb in the study I and nine limbs in the study II) surgery would have been performed on the basis of the clinical and HHD findings alone. In both of these studies, although a selective approach was used in the assessment of the HHD finding in the popliteal fossa, inaccurate operations were proposed on the basis of the clinical and HHD examinations.

Surgical registrars working on the basis of clinical the findings failed to correctly plan the treatment in 21 (26%) of the 80 proposed operations. HHD corrected these errors in 13/21 (62%) limbs by revealing the superficial truncal vein reflux. However, the HHD examination guided the treatment plan incorrectly in one limb, because of false venous reflux originating from a superficial epigastric vein at the SFJ and missed SPJ reflux.

Duplex ultrasonography or venous fluoroscopy examinations were requested in 37 (26%) cases after the assessment made by the surgical registrars. Clinical and HHD examinations performed by the consultant surgeon eliminated the need for special investigations in most cases (30/37).

In study I, surgically important anatomical findings were identified in three limbs by duplex scanning. After duplex scanning, the use of contrast medium examinations turned out to be unnecessary, because ultrasound examination was sufficiently informative of the venous anatomy. In study II, duplex scanning was requested for 20 (14 %) limbs after the HHD examination. The most common indication was a suspected but not verified reflux

in the popliteal fossa or suspected anatomical variations. Anatomical findings of surgical interest were identified in seven limbs by duplex scanning.

## **5.2 Feasibility of endovenous obliteration (III)**

The initial technical success rate of the procedures was 100 %. The mean follow-up time was 9.6 (SD 3.8) months. Twenty-two (73%) limbs were treated successfully. Four patients (4 limbs) had saphenous reflux in the treated proximal segment three months after the procedure. No further follow-up was done on these patients. The last follow-up duplex ultrasonography showed segmental flow in the treated LSV in 4 legs (13.3 %) with incomplete vein obliteration. Altogether, there were 8 cases (26.7 %) with vein recanalization.

At the time of the last follow-up visit, only one patient had swelling and pain as venous reflux- and varicosity-related symptoms. In three legs, recurrent or new varicosities had developed, all being associated with recurrent reflux. CEAP clinical class improved for up to 3 months. Mild deterioration of the CEAP clinical class during further follow-up was, without exceptions, associated with teleangiectasies in the area of hook phlebectomies. The patients were comfortable enough to resume their normal activities within a few days (median period, 4 days).

Early complications were noted in three patients. Paresthesia in the area of the saphenous nerve occurred in 3 legs (10%) of 2 patients at 6 months. Two patients developed apparent clinical phlebitis with pain, tenderness, and erythema within 1 to 6 weeks after treatment, which resulted in permanent string-like pigmented skin lesions in the thigh. There was one second-degree burn requiring systemic antibiotics and surgical drainage of an infected underlying hematoma (Table 12).

## **5.3 Comparison of results after endovenous obliteration vs. stripping operation (IV)**

The procedures were carried out on a day surgery basis, with the exception of two cases, where the patients (one from each group) had to stay in hospital overnight for social reasons. As evidence of successful standardization of general anesthesia, there were no significant differences in the BIS index, sevoflurane-MAC, immediate recovery from anesthesia or home readiness.

### ***5.3.1 Efficacy of endovenous obliteration and stripping operation and related complications***

The mean follow-up time was 50 days in both groups. All procedures were successful. There was no significant difference in the average decrease of VCSS between the two

groups. The overall complication rates were similar in the two groups, although there was a difference in the distribution of the types of complication as shown in Table 12.

*Table 12. Postoperative complications after endovenous obliteration (III and IV) and stripping operation (IV).*

Complication	Endovenous obliteration (n = 30) Study III	Endovenous obliteration (n = 15) Study IV	Stripping operation (n = 13) Study IV
Vein perforation	2 (7 %)	-	-
Saphenous nerve paresthesia	3 (10 %)	2 (13 %)	3 (23 %)
Clinical thrombophlebitis	2 (7 %)	3 (20 %)	-
Local hematoma	-	1 (7 %)	4 (31 %)
Thermal skin injury	1 (3 %)	1 (7 %)	-
Total	8 (27 %)	7 (47 %)	7 (54 %)

Figures are numbers and percentages of patients.

### **5.3.2 Sick leave and postoperative convalescence**

The patients in the endovenous obliteration group recovered faster and had significantly shorter sick leaves [6.5 (SD 3.3) vs. 15.6 (SD 6.0), 95 % CI 5.4 to 12.9,  $p < 0.001$ , TT]. There was an even more distinct difference in the patients' own assessment of the length of sick leave required. A positive correlation between age and sick leave ( $r = 0.37$ ,  $P = 0.012$ ) was observed. Six patients from the stripping group and one patient from the endovenous obliteration group visited the outpatient clinic two weeks after the operation because they felt themselves unfit to return to work.

The average VAS pain scores at rest, on standing and on walking were significantly lower in the endovenous obliteration group than in the stripping group. The differences were especially clear from the fifth to the 14<sup>th</sup> postoperative day. The median difference from the baseline value of the health-related quality of life parameter 'bodily pain' was also significantly lower in the endovenous obliteration group one week after the operation. A similar difference was noted in the median physical functioning based on the quality of life index (RAND-36) one week postoperatively.

### **5.3.3 Procedure-related costs**

The variable costs of the conventional operations were about half of the endovenous obliteration costs. The mean operation time and operating room time were significantly longer in the endovenous obliteration group. The indirect costs had a significant impact on the total societal costs, which were at least USD 300 higher per operation in the stripping group. The sensitivity analysis showed that the effect of using only half of the indirect costs was great, especially in the conventional group. If half of the indirect costs

are included in the cost analysis, endovenous obliteration becomes cost-saving after about 150 operations per year.

## 6 Discussion

### 6.1 Diagnostic methods (I-II)

In the studies I and II, we performed both ultrasound examinations with the Valsalva maneuver in a semisupine position, to examine the SFJ and the LSV trunk. This technique has proved to be easy, inexpensive and reliable (DePalma *et al.* 1993; Masuda *et al.* 1994). The HHD and duplex ultrasonography examinations of the popliteal fossa were carried out with the patient standing, as probe placement is inconvenient in the semisupine position. Based on our own experiences, when examining the SPJ and the SSV trunk, reflux insonated with the calf compression technique is more practical and reliable than that done using the Valsalva manoeuvre in an upright position. Thus, our techniques differ from the methods used in the previous studies, in which compression test was mainly used (Table 6). However, it has been shown that different techniques and positions can be used in HHD and duplex ultrasonography examinations with equal reliability (Masuda *et al.* 1994). Therefore, we consider the Valsalva manoeuvre to have been of any relevance importance for the results.

The studies I and II showed the overall accuracy of hand-held Doppler compared with duplex scanning of the superficial venous junctions and vein trunks to be lower than in some other reports (Mitchell & Darke 1987; Quigley *et al.* 1992). A possible reason for such a finding is that the present study was run in a surgical outpatient department with a homogeneous but unselected study population and without a dedicated vascular laboratory. We included in these studies (I-II) only patients with primary, uncomplicated and previously untreated CVD, because patients with recurrent or more severe CVD (CEAP clinical class 5-6) are clearly better evaluated by duplex ultrasonography (Kent & Weston 1998a).

Our results in the studies I and II are in accordance with some previous studies on the inability of HHD to accurately identify or exclude venous reflux (DePalma *et al.* 1993), especially in the popliteal fossa, where the sensitivity of HHD was not acceptable (study II). Also, the sensitivity of HHD on the SFJ was rather unsatisfactory, whereas in other studies it has ranged from 48% (DePalma *et al.* 1993) to 92-93% (Salaman *et al.* 1995; Kent & Weston 1998a). The results of these studies (I-II) clearly show that HHD failed to detect any reflux at different levels in a large number of cases, and the number of

instances of false positive reflux detected by HHD was not irrelevant, either. Thus, our results are also in accordance with the previous studies showing that, in primary, uncomplicated varicose veins, the accuracy of HHD, although significantly better than that of clinical tests, is still unsatisfactory (DePalma *et al.* 1993; Singh *et al.* 1997; Mercer *et al.* 1998; Wills *et al.* 1998; Jutley *et al.* 2001).

## 6.2 Planning of the treatment (I-II)

An adequate preoperative evaluation is of paramount importance in the process of decision-making as to whether or not to operate patients with varicose veins and which surgical strategy would be the most appropriate. Previously, not much attention has been paid to the influence of preoperative examinations on the treatment plan for patients with mild CVD. According to the results of study II, systematic use of HHD reduces the incidence of incorrectly planned surgical treatment and also the need for special investigations in the planning of surgery for primary CVD. The majority of operations for LSV insufficiency can be performed on the basis of clinical examination and hand-held Doppler findings if the assessment is done by an experienced surgeon. However, HHD may be misleading in the selection of the method of operation for primary varicose veins. Therefore, it is important to know the pitfalls of HHD.

In the series by Kent and Weston (Kent & Weston 1998a), if the operations had been planned on the basis of the HHD findings, as compared with the duplex findings, appropriate surgical treatment would have been performed in 70% of cases, more extensive surgery in 23% and inadequate surgery in 7%. In our studies I and II, about 10 % of the treatment plans were modified on the basis of the duplex ultrasound findings. Although a selective approach was used in the assessment of the HHD findings on the popliteal fossa, inaccurate operations were proposed on the basis of the clinical and HHD examinations. A considerable number of false estimations were associated with problems in the differential diagnosis of SFJ or SPJ reflux. The most serious mistakes would have occurred if a competent superficial vein had been ligated and stripped.

In paper I, we concluded that duplex ultrasonography should be used selectively in patients with suspected SPJ reflux or equivocal HHD findings. Although the results of these studies were similar, the conclusions presented in study II were quite different. This can be attributed to the improvement of my knowledge and experience in the preoperative assessment of CVD. During this research project, I have started to think that the only way to reduce recurrence rates is probably to perform as accurate a preoperative diagnosis as possible. Routine use of duplex examination should certainly minimize the sources of error in the assessment of primary varicose veins.

In practice, however, it is difficult to apply this recommendation to the strict schedules in small day surgery units, where most patients with mild CVD are treated. Currently in Finland only university hospitals and large central hospitals are equipped with vascular laboratories and duplex ultrasonography facilities for routine venous duplex examinations. In order to meet the modern standards of venous diagnosis, access to venous duplex scanning should be available in all surgical units operating on CVD. The

resources should be directed to proper preoperative evaluation and consequently, reduction of the high recurrence rates.

In the assessment of primary uncomplicated CVD, total lower leg venous mapping would be unnecessary. Duplex scanning can be directed to the suspected venous junctions and segments. The detection of variable venous anatomy also facilitates the planning of operative treatment. This practice would not require too much extra resources at the busy surgical outpatient clinics. Also, the costs associated with the use of duplex ultrasonography equipment would not be too high per examination, in view of how common mild CVD is in the population.

The results of these studies (I, II) will probably not solve the controversy of whether duplex ultrasound should be performed preoperatively on all patients with primary uncomplicated CVD, but they certainly seem to lend support to such a conclusion, as previously also claimed by other authors (DePalma *et al.* 1993; Singh *et al.* 1997; Mercer *et al.* 1998; Wills *et al.* 1998; Jutley *et al.* 2001). A randomised trial to compare preoperative HHD and duplex ultrasonography with long postoperative follow-up is needed to demonstrate whether the systematic use of duplex ultrasonography can ultimately prove cost-effective by reducing the recurrence of varicose veins.

### **6.3 Feasibility of endovenous obliteration (III)**

The results in the reports of the Endovenous Reflux Management and VNUS Closure Treatment Study (Chandler *et al.* 2000a; Manfrini *et al.* 2000) were based on international multicentre studies. The participants were a heterogeneous group of general, vascular and dermatologic surgeons, radiologists and dermatologists. At the beginning of the study there was only scant knowledge about the procedure. The technical details of the procedure varied notably between the different centres. In 22% of cases, endovenous obliteration was combined with high ligation of the SFJ. Thus, the possibility of using only the mini-invasive technique was missed. However, in 40% of cases, stab avulsion phlebectomies were not performed. Because of this, it is not possible to compare the results of the Endovenous Reflux Management and VNUS Closure Treatment Study with those in our own series. Chandler *et al.* reported a 96% acute vein occlusion rate and at a mean follow-up of 4.9 months, 7.2% of the successfully treated veins having had recanalized (Chandler *et al.* 2000a). In our study, persisting patency or recanalization of the LSV was detected in 8 legs (26.7%). Chandler *et al.* (2000a) reported the following complication rates: clinical thrombophlebitis in 6.7%, heat-induced paresthesia in 19%, thermal skin injury in 2.7% and thrombus propagation in 1.4% of cases. Our results were rather similar to the latter postoperative complications, including saphenous nerve paresthesia in 3 legs (10%) and thermal skin injury in one limb (3.3%). There were no major complications, and the incidence of saphenous nerve paresthesia in the present study did not differ from the 7% nerve complication rate after traditional proximal greater saphenous vein stripping operations (Holme *et al.* 1990). However, a comparison of the complications of endovenous obliteration and conventional procedures is not possible on the basis of the results of this feasibility study.

In study III, we had a possibility to improve the technique of endovenous obliteration based on our previous results. The proximity of the saphenous vein to the skin should be noted in preoperative duplex scanning and the risk of skin injury can be minimized with subcutaneous saline infiltration along the route of the vein, as we currently do in all cases. However, we still consider an apparent prominent LSV trunk as a contraindication for treatment with endovenous RF resistive heating.

The relatively high incidence of early treatment failures (26.7%) may have been due to excessively fast pullback of the catheter. The radiofrequency generator is programmed to maintain the temperature of the vessel wall at 85°C, and according to the manufacturers' instructions, the catheter should be pulled back slowly enough (ca. 3 cm / min) to maintain the impedance between 95 and 125 ohms and the temperature at 85°C. In addition to the correct pullback time and temperature, we recommend routine post-treatment ultrasound assessment of the entire treated vein, combined with occasional re-treatment of incompletely contracted segments.

A methodological weakness of the study III was the lack of blinded controls. The US findings were recorded on video for a possible review. The US examinations were standardized, and in our opinion, the detection of reflux by colour duplex US is not significantly open to various interpretations. After successful obliteration, the LSV shrunk during the follow-up, appearing as a thin echogenic line or being occasionally quite indiscernible at the last follow-up examination (6 and 12 months).

Overall, our mid-term follow-up data indicate that endovenous obliteration with RF-resistive heating is a feasible method for the treatment of primary LSV insufficiency in patients with mild to moderate clinical findings.

#### **6.4 Comparison of endovenous obliteration and stripping operation (IV)**

According to our findings, endovenous obliteration resulted in less postoperative pain, shorter sick leaves and faster recovery of physical function than traditional surgery. The endovenous procedure involves higher operating costs, but has potential economical advantages for employed patients due to their ability to resume work sooner. The procedures were equally efficient in eliminating reflux in the treated LSV segments. The success rate of endovenous obliteration was noticeably better than that observed in the feasibility study (III). The postoperative changes in the CEAP classification did not differ, either. The overall complication rates were similar in the two groups. The complication rate of endovenous obliteration was higher in study IV than in study III (Table 12), although this may be explained by the more thorough follow-up in study IV.

In the present study, the minimally invasive nature of the endovenous obliteration technique resulted in reduced postoperative pain. Almost half of the patients in the stripping group complained of pain and tension in the thigh two weeks after the operation, which seemed to be the main cause of prolonged sick leaves among these patients. In addition, the pain disturbed knee motion and walking, thus delaying the recovery of normal physical function.

The patients were slightly older in the stripping group, and a positive correlation between age and sick leave emerged. According to the coefficient of determination, however, age explained only 14% of the length of the sick leave. Thus, we believe that the results were not distorted by this randomization-based difference.

Our sample included employed patients, which increased influence of the indirect costs on the cost analysis. The sensitivity analysis showed that even when 25 – 40% of the patients are retired, endovenous obliteration can be economically cost-minimizing in view of society. The possible country-specific differences in the investment costs and the cost of the catheter have relatively small effects on the average cost of endovenous obliteration. In addition, since the two alternatives required approximately the same amount of other health care resources, the differences in the values of the other cost factors do not have a significant influence on the results of the cost analysis.

The results of the previous reports on the techniques of using endovenous electro-surgical devices for venous wall collagen denaturation have been so inferior that these procedures have been used only sporadically (Politowski & Zelazny 1966; Watts 1972; O'Reilly 1977; O'Reilly 1981; Griffith *et al.* 1989; Gradman 1994). Recently developed endovenous techniques, such as cryostripping (Etienne *et al.* 1997; Garde 1994), endovenous laser obliteration (Navarro *et al.* 2001) or angioscopic techniques (Hoshino *et al.* 1997), have not gained much ground, either. Although this is still the only controlled randomized trial about endovenous obliteration, it is already used in Europe and the USA. Before endovenous treatment with RF-resistive heating can establish its place in the treatment of LSV insufficiency, technical development and more scientific proof of its possible advantages are needed. The price of the catheters should also drop to convince the hospital administration of the probable cost-effectiveness of the procedure.

In conclusion, the results of study IV indicated that endovenous obliteration may offer an advantage over conventional stripping operation in terms of reduced postoperative pain, shorter sick leaves and faster return to normal activities. Endovenous obliteration was more expensive for the hospital. The total costs, which also included the costs incurred by society due to sick leaves, were no higher than the total costs of the conventional stripping operation. More information is needed on the long-term results and recurrence rates, and larger studies are required to determine the precise role of this procedure in the treatment of primary LSV insufficiency. A thorough assessment of CVD surgery would also require a long-term cost-effectiveness or cost-benefit analysis of these alternatives.

## **7 Conclusions**

With reference to the purpose of the present investigation, the results can be summarized as follows:

1. Patients with uncomplicated primary saphenous vein insufficiency should be examined using duplex ultrasonography at least in cases where SPJ reflux is suspected or with equivocal hand-held Doppler findings.
2. Patients with mild chronic venous disease (CEAP clinical class 2-4) should not be operated based on only clinical judgement. The accuracy of hand-held Doppler examination is unsatisfactory, and Duplex ultrasonography should be considered the preoperative diagnostic method of choice in uncomplicated primary saphenous vein insufficiency.
3. Endovenous obliteration employing radiofrequency-resistive heating is a feasible procedure and a mini-invasive alternative for the treatment of primary long saphenous vein insufficiency.
4. Endovenous obliteration may offer advantages over the conventional stripping operation in terms of reduced postoperative pain, shorter sick leaves and faster return to normal activities and it appears to be cost-saving among employed patients in mid-term evaluation.

## 8 References

- Abu-Own A, Scurr JH & Coleridge Smith PD (1994) Saphenous vein reflux without incompetence at the saphenofemoral junction. *Br J Surg* 81(10): 1452-1454.
- Adhikari A, Criqui MH, Wooll V, Denenberg JO, Fronck A, Langer RD & Klauber M (2000) The epidemiology of chronic venous diseases. *Phlebology* 15: 2-18.
- Aiono S, Simmons MJ, Galland RB & Magee TR (2001) Is a palpable short saphenous vein a useful clinical sign in varicose vein assessment? *Ann R Coll Surg Engl* 83(2): 105-107.
- Albanese AR, Albanese AM & Albanese EF (1969) Lateral subdermic varicose vein system of the legs. Its surgical treatment by the chiseling tube method. *Vasc Surg* 3(2): 81-89.
- Allegra C & Carlizza A (2000) Oedema in chronic venous insufficiency: Pathophysiology and investigation. *Phlebology* 15: 122-125.
- Baker DM, Turnbull NB, Pearson JC & Makin GS (1995) How successful is varicose vein surgery? A patient outcome study following varicose vein surgery using the SF-36 Health Assessment Questionnaire. *Eur J Vasc Endovasc Surg* 9(3): 299-304.
- Baker SR, Burnard KG, Sommerville KM, Lea Thomas M, Wilson NM & Browse NL (1993) Comparison of venous reflux assessed by duplex scanning and descending phlebography in chronic venous disease. *Lancet* 341: 400-403.
- Baldt MM, Bohler K, Zontsich T, Bankier AA, Bretenseher M, Schneider B & Mostbeck GH (1996) Preoperative imaging of lower extremity varicose veins: color coded duplex sonography or venography. *J Ultrasound Med* 15(2): 143-154.
- Belcaro G, Labropoulos N, Christopoulos D, Vasdekis S, Laurora G, Cesarone MR & Nicolaides A (1993) Noninvasive tests in venous insufficiency. *J Cardiovasc Surg (Torino)* 34(1): 3-11.
- Belcaro G, Nicolaides AN, Ricci A, Dugall M, Errichi BM, Vasdekis S & Chritopoulos D (2000) Endovascular sclerotherapy, surgery, and surgery plus sclerotherapy in superficial venous incompetence: a randomized, 10-year follow-up trial--final results. *Angiology* 51(7): 529-534.
- Bello M, Scriven M, Hartshorne T & London NJ (1999) Venous ulceration and continuous flow in the long saphenous vein. *Eur J Vasc Endovasc Surg* 17(2): 111-114.
- Bergan JJ (1996) New technology and recurrent varicose veins. *Lancet* 348(9022): 210-211.
- Bergan JJ (1998) A unifying concept of primary venous insufficiency. *Dermatol Surg* 24(4): 425-428.
- Bladin C & Royle JP (1987) Acquisition of skills required for use of Doppler ultrasound and the assessment of varicose veins. *Aust N Z J Surg* 57(4): 225-226.

- Blomquist HE (1968) The surgical anatomy of the sapheno-femoral junction. *Ann Chir Gynaecol Fenn* 57(3): 325-328.
- Boivin P, Cornu-Thenard A & Charpak Y (2000) Pregnancy-induced changes in lower extremity superficial veins: an ultrasound scan study. *J Vasc Surg* 32(3): 570-574.
- Bond R, Whyman MR, Wilkins DC, Walker Aj & Ashley S (1999) A randomised trial of different compression dressings following varicose vein surgery. *Phlebology* 14: 9-11.
- Bradbury A, Evans C, Allan P, Lee AJ, Ruckley CV & Fowkes FG (1999) What are the symptoms of varicose veins? Edinburgh vein study cross sectional population survey. *Bmj* 318(7180): 353-356.
- Bradbury A, Evans CJ, Allan P, Lee AJ, Ruckley CV & Fowkes FG (2000) The relationship between lower limb symptoms and superficial and deep venous reflux on duplex ultrasonography: The Edinburgh Vein Study. *J Vasc Surg* 32(5): 921-931.
- Bradbury A, Stonebridge PA, Callam MJ, Walker AJ, Allan P, Beggs I & Ruckley CV (1994) Recurrent varicose veins: assessment of the saphenofemoral junction. *Br J Surg* 81(3): 373-375.
- Braithwaite BD (2001) What is new in venous surgery. *Phlebology* 16: 3-5.
- Brand FN, Dannenberg AL, Abbott RD & Kannel WB (1988) The epidemiology of varicose veins: the Framingham Study. *Am J Prev Med* 4(2): 96-101.
- Cabrera J, Cabrera Jr. J & Carcia-Olmedo MA (2000) Treatment of varicose long saphenous vein with sclerosant in microfoam form: Long-term outcomes. *Phlebology* 15: 19-23.
- Caggiati A & Bergan JJ (2001) The saphenous vein: Derivation of its name and its relevant anatomy. *J Vasc Surg* 34(2): 235-239.
- Caggiati A, Ricci S, Laghi A, Luccichenti G & Pavone P (2001) Three-dimensional contrastless varicography by spiral computed tomography. *Eur J Vasc Endovasc Surg* 21(4): 374-376.
- Callam MJ (1994) Epidemiology of varicose veins. *Br J Surg* 81(2): 167-173.
- Campbell WB, Halim AS, Aertssen A, Ridler BM, Thompson JF & Niblett PG (1996) The place of duplex scanning for varicose veins and common venous problems. *Ann R Coll Surg Engl* 78(6): 490-493.
- Campbell WB, Niblett PG, Ridler BM, Peters AS & Thompson JF (1997) Hand-held Doppler as a screening test in primary varicose veins. *Br J Surg* 84(11): 1541-1543.
- Campbell WB & Ridler BM (1995) Varicose vein surgery and deep vein thrombosis. *Br J Surg* 82(11): 1494-1497.
- Chan A, Chisholm I & Royle JP (1983) The use of directional Doppler ultrasound in the assessment of saphenofemoral incompetence. *Aust N Z J Surg* 53(5): 399-402.
- Chandler JG, Pichot O, Sessa C, Schuller-Petrovic S, Kabnick LS & Bergan JJ (2000a) Treatment of primary venous insufficiency by endovenous saphenous vein obliteration. *Vasc Surg* 34(3): 201-204.
- Chandler JG, Pichot O, Sessa C, Schuller-Petrovic S, Osse FJ & Bergan JJ (2000b) Defining the role of extended saphenofemoral junction ligation: a prospective comparative study. *J Vasc Surg* 32(5): 941-953.
- Chen SS, Wright NT & Humphrey JD (1998) Heat-induced changes in the mechanics of a collagenous tissue: Isothermal, isotonic shrinkage. *J Biomech Eng* 120: 382-388.
- Ciardullo AV, Panico S, Bellati C, Rubba P, Rinaldi S, Iannuzzi A, Cioffi V, Iannuzzi G Berrino F (2000) High endogenous estradiol is associated with increased venous distensibility and clinical evidence of varicose veins in menopausal women. *J Vasc Surg* 32(3): 544-549.
- Coleridge Smith PD (1999) Duplex ultrasonography and the investigation of venous disease. *Phlebology* 14:137-138.

- Corbett R & Jayakumar KN (1989) Clean up varicose vein surgery - use a tourniquet. *Ann R Coll Surg Engl* 71(1): 57-58.
- Cordts PR & Gawley TS (1996) Anatomic and physiologic changes in lower extremity venous hemodynamics associated with pregnancy. *J Vasc Surg* 24(5): 763-767.
- Cornu-Thenard A, Boivin P, Baud JM, De Vincenzi I & Carpentier PH (1994) Importance of the familial factor in varicose disease. Clinical study of 134 families. *J Dermatol Surg Oncol* 20(5): 318-326.
- Cotton L (1961) Varicose veins: gross anatomy and development. *Br J Surg* 48: 589-598.
- Critchley G, Handa A, Maw A, Harvey A, Harvey MR & Corbett CR (1997) Complications of varicose vein surgery. *Ann R Coll Surg Engl* 79(2): 105-110.
- Darke SG, Vetrivel S, Foy DM, Smith S & Baker S (1997) A comparison of duplex scanning and continuous wave Doppler in the assessment of primary and uncomplicated varicose veins. *Eur J Vasc Endovasc Surg* 14(6): 457-461.
- Davies AH, Steffen C, Cosgrove C & Wilkins DC (1995) Varicose vein surgery: patient satisfaction. *J R Coll Surg Edinb* 40(5): 298-299.
- De Maeseneer MG, De Hert SG, Van Schils PE, Vanmaele RG & Eyskens EJ (1993) Preoperative colour-coded duplex examination of the saphenopopliteal junction in recurrent varicosity of the short saphenous vein. *Cardiovasc Surg* 1(6): 680-683.
- De Maeseneer MG, Tielliu IF, Van Schil PE, De Hert SG & Eyskens EJ (1999) Clinical relevance of neovascularisation on duplex ultrasound in the long-term follow-up after varicose veins operation. *Phlebology* 14(3): 118-122.
- De Maeseneer MG, Van Schil PE, Philippe MM, Vanmaele RG & Eyskens EJ (1995) Is recurrence of varicose veins after surgery unavoidable? *Acta Chir Belg* 95(1): 21-26.
- DePalma RG, Hart MT, Zanin L & Massarin EH (1993) Physical examination, Doppler ultrasound and colour flow duplex scanning: Guides to therapy for primary varicose veins. *Phlebology* 8: 7-11.
- Dixon PM (1996) Duplex ultrasound in the pre-operative assessment of varicose veins. *Australas Radiol* 40(4): 416-421.
- Dormandy J & Thomas P (1989) The role of leucocytes in chronic venous insufficiency and venous leg ulceration. *Phlebology* 4: 113.
- Duffy DM (1988) Small vessel sclerotherapy: an overview. In: Callen JP, Dahl MV & Golitz LE (eds) *Advances in dermatology*, vol. 3, Year Book, Chigago, p 221-242.
- Durkin MT, Turton EP, Scott DJ & Berridge DC (1999) A prospective randomised trial of PIN versus conventional stripping in varicose vein surgery. *Ann R Coll Surg Engl* 81(3): 171-174.
- Dwerryhouse S, Davies B, Harradine K & Earnshaw JJ (1999) Stripping the long saphenous vein reduces the rate of reoperation for recurrent varicose veins: five-year results of a randomized trial. *J Vasc Surg* 29(4): 589-592.
- Earnshaw JJ, Davies B, Harradine K & Heather BP (1998) Preliminary results of PTFE patch saphenoplasty to prevent neovascularization leading to recurrent varicose veins. *Phlebology* 13: 10-13.
- Etienne G, Constantin JM & Hevia M (1997) Cryo-stripping: an alternative to perforate-invaginate stripping. *Ann Vasc Surg* 11(3): 325-328.
- Evans CJ, Allan PL, Lee AJ, Bradbury AW, Ruckley CV & Fowkes FG (1998) Prevalence of venous reflux in the general population on duplex scanning: the Edinburgh vein study. *J Vasc Surg* 28(5): 767-776.

- Evans CJ, Fowkes FG, Hajivassiliou CA, Harper DR & Ruckley CV (1994) Epidemiology of varicose veins. A review. *Int Angiol* 13(3): 263-270.
- Evans CJ, Fowkes FG, Ruckley CV & Lee AJ (1999) Prevalence of varicose veins and chronic venous insufficiency in men and women in the general population: Edinburgh Vein Study. *J Epidemiol Community Health* 53(3): 149-153.
- Farrah J & Shami SK (2001) Patterns of incompetence in patients with recurrent varicose veins: A duplex ultrasound study. *Phlebology* 16:34-37.
- Fischer R, Linde N, Duff C, Jeanneret C, Chandler JG & Seeber P (2001) Late recurrent saphenofemoral junction reflux after ligation and stripping of the greater saphenous vein. *J Vasc Surg* 34(2): 236-240.
- Foldi M & Idiazabal G (2000) The role of operative management of varicose veins in patients with lymphedema and/or lipedema of the legs. *Lymphology* 33(4): 167-171.
- Folse R (1970) Directional flow detection for localizing venous valvular incompetency. *Surgery* 67: 114-121.
- Galland RB & Magee TR (1998) Survey of changes in the provision of vascular surgical services in the Oxford Region over 5 years. *Br J Surg* 85(5): 637-640.
- Garde C (1994) Cryosurgery of varicose veins. *J Dermatol Surg Oncol* 20(1): 56-58.
- Georgiev M (1998) The preoperative duplex examination. *Dermatol Surg* 24(4): 433-440.
- Glass GM (1987a) Neovascularisation in recurrence of the varicose great saphenous vein following transection. *Phlebology* 2: 81-91.
- Glass GM (1987b) Neovascularisation in restoration of continuity of the not femoral vein following surgical interruption. *Phlebology* 2:1-6.
- Glass GM (1988) Neovascularization in recurrence of varices of the great saphenous vein in the groin: phlebography. *Angiology* 39(7 Pt 1): 577-582.
- Glass GM (1998) Prevention of sapheno-femoral and saphenopopliteal recurrence of varicose veins by forming a partition to contain neovascularization. *Phlebology* 13: 3-9.
- Goldman MP (2000) Closure of the greater saphenous vein with endoluminal radiofrequency thermal heating of the vein wall in combination with ambulatory phlebectomy: preliminary 6-month follow-up. *Dermatol Surg* 26(5): 452-456.
- Goldman MP & Fronek A (1989) Anatomy and pathophysiology of varicose veins. *J Dermatol Surg Oncol* 15(2): 138-145.
- Goren G & Yellin AE (1994) Invaginated axial saphenectomy by a semirigid stripper: perforate-invaginate stripping. *J Vasc Surg* 20(6): 970-977.
- Gradman WS (1994) Venoscopic obliteration of variceal tributaries using monopolar electrocautery. Preliminary report. *J Dermatol Surg Oncol* 20(7): 482-485.
- Griffith CD, Dennis MJ, Blundell JW & Hopkinson BR (1989) Bipolar diathermy treatment of long saphenous vein varicosities. *J R Coll Surg Edinb* 34(5): 256-257.
- Hanrahan LM, Araki CT, Rodriguez AA, Kechejian GJ, LaMorte WW & Menzoian JO (1991) Distribution of valvular incompetence in patients with venous stasis ulceration. *J Vasc Surg* 13(6): 805-811.
- Hanson JN, Ascher E, DePippo P, Lorensen E, Scheinman M, Yorkovich W & Hingorani A (1998) Saphenous vein thrombophlebitis (SVT): a deceptively benign disease. *J Vasc Surg* 27(4): 677-680.
- Heyerdale WW & Stalker LK (1941) The management of varicose veins of the lower extremities. *Ann Surg* 114: 1042-1049.

- Hoare MC & Royle JP (1984) Doppler ultrasound detection of saphenofemoral and saphenopopliteal incompetence and operative venography to ensure precise saphenopopliteal ligation. *Aust N Z J Surg* 54(1): 49-52.
- Hobbs JT (1974) Surgery and sclerotherapy in the treatment of varicose veins. A random trial. *Arch Surg* 109(6): 793-796.
- Hobbs JT (1980) Peroperative venography to ensure accurate sapheno-popliteal vein ligation. *Br Med J* 280(6231): 1578-1579.
- Hobbs JT (1986) Errors in the differential diagnosis of incompetence of the popliteal vein and short saphenous vein by Doppler ultrasound. *J Cardiovasc Surg (Torino)* 27(2): 169-174.
- Hobbs JT (1990) The pelvic congestion syndrome. *Br J Hosp Med* 43(3): 200-206.
- Hollingsworth SJ, Tang CB & Barker SGE (2001) Primary varicose veins in the presence of an intact sapheno-femoral junction. *Phlebology* 16: 68-72.
- Holme JB, Holme K & Sorensen LS (1988) The anatomic relationship between the long saphenous vein and the saphenous nerve. Relevance for radical varicose vein surgery. *Acta Chir Scand* 154(11-12): 631-633.
- Holme JB, Skajaa K & Holme K (1990) Incidence of lesions of the saphenous nerve after partial or complete stripping of the long saphenous vein. *Acta Chir Scand* 156(2): 145-148.
- Hoshino S, Satokawa H, Takase S & Midorikawa H (1997) External valvuloplasty for primary valvular incompetence of the lower limbs using angioscopy. *Int J Angiol* 6: 137-141.
- Huber O, Bounameaux H, Borst F & Rohner A (1992) Postoperative pulmonary embolism after hospital discharge. An underestimated risk. *Arch Surg* 127: 310-313.
- Ik Kim D, Boong Lee B & Bergan JJ (1999) Venous hemodynamic changes after external banding valvuloplasty with varicosectomy in the treatment of primary varicose veins. *J Cardiovasc Surg (Torino)* 40(4): 567-570.
- Incandela L, Belcaro G, Nicolaidis AN, Agus G, Errichi BM, Cesarone MR, De Sanctis MT, Ricci A, Sabetai M, Mondani P, De Angelis R, Bavera P, Griffin M & Geruulakos G (2000) Superficial vein valve repair with a new external valve support (EVS). The IMES (International Multicenter EVS Study). *Angiology* 51(8 Pt 2): S39-52.
- Jakobsen BH (1979) The value of different forms of treatment for varicose veins. *Br J Surg* 66(3): 182-184.
- Jeanneret C, Labs KH, Aschwanden M, Hoffman U & Jager K (1999) Physiological reflux and venous diameter change in the proximal lower limb veins during a standardised Valsalva manoeuvre. *Eur J Vasc Endovasc Surg* 17(5): 398-403.
- Jiang P, van Rij AM, Christie R, Hill G, Solomon C & Thomson I (1999) Recurrent varicose veins: patterns of reflux and clinical severity. *Cardiovasc Surg* 7(3): 332-339.
- Jones HJS & Derodra JK (1997) Restless legs syndrome - a review. *Eur J Vasc Endovasc Surg* 14: 430-432.
- Jones L, Braithwaite BD, Selwyn D, Cooke S & Earnshaw JJ (1996) Neovascularisation is the principal cause of varicose vein recurrence: results of a randomised trial of stripping the long saphenous vein. *Eur J Vasc Endovasc Surg* 12(4): 442-445.
- Jungbeck C, Thulin I, Darenheim C & Norgren L (1997) Graduated compression treatment in patients with chronic venous insufficiency: a study comparing low and medium grade compression stockings. *Phlebology* 12: 142-145.
- Jutley RS, Cadle I & Cross KS (2001) Preoperative assessment of primary varicose veins: a duplex study of venous incompetence. *Eur J Vasc Endovasc Surg* 21(4): 370-373.

- Katsamouris AN, Kardoulas DG & Gourtsoyiannis N (1994) The nature of lower extremity venous insufficiency in patients with primary varicose veins. *Eur J Vasc Surg* 8(4): 464-471.
- Keller WL (1905) A new method of extirpating the internal saphenous and similar veins in varicose conditions. A preliminary report. *NY Med J* 82: 385.
- Kent PJ, Maughan J, Burniston M, Nicholas T, Parkin A & Robinson PJ (1999) Perforation-invagination (PIN) stripping of the long saphenous vein reduces thigh haematoma formation in varicose vein surgery. *Phlebology* 14: 43-47.
- Kent PJ & Weston MJ (1998a) Duplex scanning may be used selectively in patients with primary varicose veins. *Ann R Coll Surg Engl* 80(6): 388-393.
- Kent PJ & Weston MJ (1998b) Should body mass index affect the choice of probe frequency in the clinical assessment of varicose veins using hand-held Doppler. *Phlebology* 13: 31-35.
- Khan B, Khan S, Greaney MG & Blair SD (1996) Prospective randomized trial comparing sequential avulsion with stripping of the long saphenous vein. *Br J Surg* 83(11): 1559-1562.
- Kim J, Richards S & Kent PJ (2000) Clinical examination of varicose veins - a validation study. *Ann R Coll Surg Engl* 82(3): 171-175.
- Kistner RL, Eklof B & Masuda EM (1996) Diagnosis of chronic venous disease of the lower extremities: the CEAP classification. *Mayo Clin Proc* 71(4): 338-345.
- Kistner RL & Kamida CB (1995) 1994 update on phlebography and varicography. *Dermatol Surg* 21(1): 71-76.
- Kupinski AM, Evans SM, Khan AM, Zorn TJ, Darling RC 3<sup>rd</sup>, Chang BB, Leather RP & Shah DM (1993) Ultrasonic characterization of the saphenous vein. *Cardiovasc Surg* 1(5): 513-517.
- Labropoulos N, Kang SS, Mansour MA, Giannoukas AD, Buckman J & Baker WH (1999) Primary superficial vein reflux with competent saphenous trunk. *Eur J Vasc Endovasc Surg* 18(3): 201-206.
- Labropoulos N, Leon M, Nicolaides AN, Giannoukas AD, Volteas N & Chan P (1994a) Superficial venous insufficiency: correlation of anatomic extent of reflux with clinical symptoms and signs. *J Vasc Surg* 20(6): 953-958.
- Labropoulos N, Leon M, Volteas N & Nicolaides AN (1994b) Acute and long-term effect of elastic stockings in patients with varicose veins. *Int Angiol* 13(2): 119-123.
- Lacroix H, Nevelsteen A & Suy R (1999) Invaginating versus classic stripping of the long saphenous vein. A randomized prospective study. *Acta Chir Belg* 99(1): 22-25.
- Laurikka J, Läärä E, Sisto T, Tarkka M, Auvinen O & Hakama M (1995) Misclassification in a questionnaire survey of varicose veins. *J Clin Epidemiol* 48(9): 1175-1178.
- Laurikka J, Sisto T, Auvinen O, Tarkka M, Läärä E & Hakama M (1993) Varicose veins in a Finnish population aged 40-60. *J Epidemiol Community Health* 47(5): 355-357.
- Lee AJ, Evans CJ, Hau CM, Allan PL & Fowkes FGR (1999) Pregnancy, oral contraception, hormone replacement therapy and the occurrence of varicose veins: Edinburgh vein study. *Phlebology* 14(3): 111-117.
- Lees T, Singh S, Beard J, Spencer P & Rigby C (1997) Prospective audit of surgery for varicose veins. *Br J Surg* 84(1): 44-46.
- Lees TA, Beard JD, Ridler BM & Szymanska T (1999) A survey of the current management of varicose veins by members of the Vascular Surgical Society. *Ann R Coll Surg Engl* 81(6): 407-417.
- Lees TA & Lambert D (1993) Patterns of venous reflux in limbs with skin changes associated with chronic venous insufficiency. *Br J Surg* 80(6): 725-728.

- Lucertini G, Viacava A, Grana A & Belardi P (1999) Injury to the common peroneal nerve during surgery of the lesser saphenous vein. *Phlebology* 14: 26-28.
- Mackay DC, Summerton DJ & Walker AJ (1995) The early morbidity of varicose vein surgery. *J R Nav Med Serv* 81(1): 42-46.
- Majeed AW, Brown S, Williams N, Hannay DR & Johnson AG (1995) Variations in medical attitudes to postoperative recovery period. *Bmj* 311(7000): 296.
- Manfrini S, Gasbarro V, Danielsson G, Norgren L, Chandler JG, Lennox AF, Zarka ZA & Nicolaides AN (2000) Endovenous management of saphenous vein reflux. Endovenous Reflux Management Study Group. *J Vasc Surg* 32(2): 330-342.
- Mariani F, Bianchi V & Mancini S (2000) Teleangiectases in venous insufficiency: Point of reflux and treatment. *Phlebology* 15: 38-42.
- Mashiah A, Berman V, Thole HH, Rose SS, Pasik S, Schwarz H & Ben-Hur H (1999) Estrogen and progesterone receptors in normal and varicose saphenous veins. *Cardiovasc Surg* 7(3) : 327-331.
- Mastroroberto P, Chello M & Marchese AR (1992) Distribution of valvular incompetence in patients with venous stasis ulceration. *J Vasc Surg* 16(2): 307.
- Masuda EM & Kistner RL (1992) Prospective comparison of duplex scanning and descending venography in the assessment of venous insufficiency. *Am J Surg* 164: 254-259.
- Masuda EM, Kistner RL & Eklof B (1994) Prospective study of duplex scanning for venous reflux: comparison of Valsalva and pneumatic cuff techniques in the reverse Trendelenburg and standing positions. *J Vasc Surg* 20(5): 711-720.
- Mayo CH (1906) Treatment of varicose veins. *Surg Gynecol Obstet* 2: 385-388.
- McIrvine AJ, Corbett CR, Aston NO, Sherriff EA, Wiseman PA & Jamieson CW (1984) The demonstration of saphenofemoral incompetence; doppler ultrasound compared with standard clinical tests. *Br J Surg* 71(7): 509-510.
- Mercer KG, Scott DJ & Berridge DC (1998) Preoperative duplex imaging is required before all operations for primary varicose veins. *Br J Surg* 85(11): 1495-1497.
- Miller GV, Lewis WG, Sainsbury JR & MacDonald RC (1996) Morbidity of varicose vein surgery: auditing the benefit of changing clinical practice. *Ann R Coll Surg Engl* 78(4): 345-349.
- Mitchell DC & Darke SG (1987) The assessment of primary varicose veins by Doppler ultrasound - the role of sapheno-popliteal incompetence and the short saphenous systems in calf varicosities. *Eur J Vasc Surg* 1(2): 113-115.
- Navarro L, Min R & Bone C (2001) Endovenous laser: a new minimally invasive method of treatment for varicose veins - preliminary observations using an 810 nm diode laser. *Dermatol Surg* 27(2): 117-122.
- Neglen P (2001) Long saphenous stripping is favored in treating varicose veins. *Dermatol Surg* 27(10): 901-902.
- Neglen P, Einarsson E & Eklof B (1993) The functional long-term value of different types of treatment for saphenous vein incompetence. *J Cardiovasc Surg (Torino)* 34(4): 295-301.
- Neglen P & Raju S (1992) A comparison between descending phlebography and duplex Doppler investigation in the evaluation of reflux in chronic venous insufficiency: A challenge to phlebography as the "gold standard". *J Vasc Surg* 16(5): 687-93.
- Negus D (1986) Should the incompetent saphenous vein be stripped to the ankle ? *Phlebology* 1: 33-36.
- Negus D (1993) Recurrent varicose veins: a national problem. *Br J Surg* 80(7): 823-824.
- Neumann HA, De Roos KP & Veraart JC (1998) Muller's ambulatory phlebectomy and compression. *Dermatol Surg* 24(4): 471-474.

- Neumann HA (2001) Compression therapy: European regulatory affairs. *Phlebology* 15: 182-187.
- Nicolaides AN (2000) Investigation of chronic venous insufficiency: A consensus statement (France, March 5-9, 1997). *Circulation* 102(20): E126-163.
- Nyamekye I, Shephard NA, Davies B, Heather Bp & Earnshaw JJ (1998) Clinicopathological evidence that neovascularisation is a cause of recurrent varicose veins. *Eur J Vasc Endovasc Surg* 15(5): 412-415.
- Oesch A (1993) "Pin-Stripping": a novel method of atraumatic stripping. *Phlebology* 8: 171-173.
- O'Reilly K (1977) Endovenous diathermy sclerosis of varicose veins. *Aust N Z J Surg* 47(3): 393-395.
- O'Reilly K (1981) A technique of diathermy sclerosis of varicose veins. *Aust N Z J Surg* 51(4): 379-382.
- Otley CC & Mensink LM (1999) The phlebectomy probe: a new and useful instrument for ambulatory phlebectomy. *Dermatol Surg* 25(7): 573-575.
- Padberg Jr FT, Maniker AH, Carmel G, Pappas PJ, Silva MB & Hobson RW (1999) Sensory impairment: A feature of chronic venous insufficiency. *J Vasc Surg* 30(5): 836-843.
- Papadakis K, Christodoulou C, Christopoulos D, Hobbs J, Malouf GM, Grigg M, Irvine A & Nicolaides A (1989) Number and anatomical distribution of incompetent thigh perforating veins. *Br J Surg* 76(6): 581-584.
- Perrin MR, Guex JJ, Ruckley CV, DePalma RG, Royle JP, Eklöf B, Nicolini P & Jantet G (2000) Recurrent varices after surgery (REVAS), a consensus document. REVAS group. *Cardiovasc Surg* 8(4): 233-245.
- Phillips GW, Paige J & Molan MP (1995) A comparison of colour duplex ultrasound with venography and varicography in the assessment of varicose veins. *Clin Radiol* 50(1): 20-25.
- Pichot O, Sessa C, Chandler JG, Nuta M & Perrin M (2000) Role of duplex imaging in endovenous obliteration for primary venous insufficiency. *J Endovasc Ther* 7(6): 451-459.
- Pleass HC & Holdsworth JD (1996) Audit of introduction of hand-held Doppler and duplex ultrasound in the management of varicose veins. *Ann R Coll Surg Engl* 78(6): 494-496.
- Politowski M & Zelazny T (1966) Complications and difficulties in electrocoagulation of varices of the lower extremities. *Surgery* 59(6): 932-934.
- Porter J, Rutherford R, Clagett GP, Cranley JJJ, O'Donnel TF, Raju S & al. (1988) Reporting standards in venous disease. *J Vasc Surg* 8: 172-181.
- Porter JM & Moneta GL (1995) Reporting standards in venous disease: an update. International Consensus Committee on Chronic Venous Disease. *J Vasc Surg* 21(4): 635-645.
- Quigley FG, Raptis S, Cashman M & Faris IB (1992) Duplex ultrasound mapping of sites of deep to superficial incompetence in primary varicose veins. *Aust N Z J Surg* 62(4): 276-278.
- Ramelet AA (1991) Muller phlebectomy. A new phlebectomy hook. *J Dermatol Surg Oncol* 17(10): 814-816.
- Raraty MGT, Greaney MG & Blair SD (1999) There is no benefit from 6 weeks`postoperative compression after varicose vein surgery: A prospective randomised trial. *Phlebology* 14(1): 21-25.
- Ricci S (1998) Ambulatory phlebectomy. Principles and evolution of the method. *Dermatol Surg* 24(4): 459-464.
- Ricci S & Caggiati A (1999) Does a double long saphenous vein exist ? *Phlebology* 14: 59-64.
- Richardson JB & Dixon M (1977) Varicose veins in tropical Africa. *Lancet* 1(8015): 791-792.
- Rivlin S (1975) The surgical cure of primary varicose veins. *Br J Surg* 62(11): 913-917.
- Royle JP (1986) Recurrent varicose veins. *World J Surg* 10(6): 944-953.

- Rutgers PH & Kitslaar PJ (1994) Randomized trial of stripping versus high ligation combined with sclerotherapy in the treatment of the incompetent greater saphenous vein. *Am J Surg* 168(4): 311-315.
- Rutherford RB, Padberg FT, Comerota AJ, Kistner RL, Meissner MH & Moneta GL (2000) Venous severity scoring: An adjunct to venous outcome assessment. *J Vasc Surg* 31(6): 1307-1312.
- Sadick NS (1992) Predisposing factors of varicose and telangiectatic leg veins. *J Dermatol Surg Oncol* 18(10): 883-886.
- Salaman RA, Fligelstone LJ, Wright N, Pugh KG, Harding KG & Lane IF (1995) Hand-held bi-directional Doppler versus colour duplex scanning in the pre-operative assessment of varicose veins. *Journal of Vascular Investigation* 4(1): 183-186.
- Sarin S, Scurr JH & Coleridge Smith PD (1992) Assessment of stripping the long saphenous vein in the treatment of primary varicose veins. *Br J Surg* 79(9): 889-893.
- Sarin S, Scurr JH & Coleridge Smith PD (1994) Stripping of the long saphenous vein in the treatment of primary varicose veins. *Br J Surg* 81(10): 1455-1458.
- Schanzer H & Skladany M (1994) Varicose vein surgery with preservation of the saphenous vein: a comparison between high ligation-avulsion versus saphenofemoral banding valvuloplasty-avulsion. *J Vasc Surg* 20(5): 684-687.
- Scott HJ, McMullin GM, Coleridge Smith PD & Scurr JH (1990) Venous disease: investigation and treatment, fact or fiction? *Ann R Coll Surg Engl* 72(3): 188-192.
- Scurr J (1990) Complications in the treatment of varicose veins. *AMVA Medical & Legal Journal* 1: 1-3.
- Scurr JH & Tibbs DJ (1997) Varicose veins and venous disorders. In: Tibbs DJ (ed) *Varicose veins, Venous disorders, and lymphatic problems in the lower limbs*. Oxford University Press, Oxford, p 3-20.
- Sethia KK & Darke SG (1984) Long saphenous incompetence as a cause of venous ulceration. *Br J Surg* 71(10): 754-755.
- Shah DM, Chang BB, Leopold PW, Corson JD, Leather RP & Karmody AM (1986) The anatomy of the greater saphenous venous system. *J Vasc Surg* 3(2): 273-283.
- Shami SK, Sarin S, Cheate TR, Scurr JH & Smith PD (1993) Venous ulcers and the superficial venous system. *J Vasc Surg* 17(3): 487-490.
- Shamiyeh A, Screnk P, Rieger R & Wayand W (1999) Endostripping: A new minimally invasive technique for limited stripping of the greater saphenous vein. *Phlebology* 14: 158-161.
- Sheppard M (1978) A procedure for the prevention of recurrent saphenofemoral incompetence. *Aust N Z J Surg* 48(3): 322-326.
- Simonetti S, Bianchi S & Martinoli C (1999) Neurophysiological and ultrasound findings in sural nerve lesions following stripping of the small saphenous vein. *Muscle Nerve* 22(12): 1724-1726.
- Singh S, Lees TA, Donlon M, Harris N & Beard JD (1997) Improving the preoperative assessment of varicose veins. *Br J Surg* 84(6): 801-802.
- Sisto T, Reunanen A, Laurikka J, Impivaara O, Heliövaara M, Knekt P & Aromaa A (1995) Prevalence and risk factors of varicose veins in lower extremities: mini-Finland health survey. *Eur J Surg* 161(6): 405-414.
- Smith JJ, Garratt AM, Guest M, Greenhalgh RM & Davies AH (1999) Evaluating and improving health-related quality of life in patients with varicose veins. *J Vasc Surg* 30(4): 710-719.

- Sobaszek A, Frimat P, Tiberguent A, Domont A, Chevalier H & Catilina P (1998) Venous insufficiency of the lower limbs and working conditions. *Phlebology* 13: 133-141.
- Somjen GM (1995) Anatomy of the superficial venous system. *Dermatol Surg* 21(1): 35-45.
- Stanhope JM (1975) Varicose veins in a population of lowland New Guinea. *Int J Epidemiol* 4(3): 221-225.
- Statistics Finland (2000) Statistical Yearbook of Finland. Painatuskeskus Oy, Helsinki, Finland.
- Stonebridge PA, Chalmers N, Beggs I, Bradbury AW & Ruckley CV (1995) Recurrent varicose veins: a varicographic analysis leading to a new practical classification. *Br J Surg* 82(1): 60-62.
- Sumner DS (1981) Venous dynamics - varicosities. *Clin Obstet Gynecol* 24(3): 743-760.
- Sumner DS & van Bemmelen PS (1997) Hemodynamics of the venous system: Calf pump and valve function. Raju S & Villavicencio JL (eds) *Surgical management of venous disease*. Williams & Wilkins, Baltimore, p 16-38.
- Sytchev GC (1985) Classification of chronic venous disorders of lower extremities and pelvis. *Int Angiol* 4: 203-206.
- Tennant WG & Ruckley CV (1996) Medico-legal action following treatment for varicose veins. *Br J Surg* 83 : 291-292.
- Tessari L, Cavezzi A & Frullini A (2001) Preliminary experience with a new sclerosing foam in the treatment of varicose veins. *Dermatol Surg* 27(1): 58-60.
- Thomas ML & Bowles JN (1985) Incompetent perforating veins: comparison of varicography and ascending phlebography. *Radiology* 154(3): 619-623.
- Thompson JF, Royle GT, Farrands PA, Najmaldin A, Clifford PC & Webster JH (1990) Varicose vein surgery using a pneumatic tourniquet: reduced blood loss and improved cosmesis. *Ann R Coll Surg Engl* 72(2): 119-121.
- Tong Y & Royle J (1994) An anatomic source of false venous reflux with continuous wave Doppler. *J Dermatol Surg Oncol* 20(10): 676-678.
- Tong Y & Royle J (1996) Recurrent varicose veins after short saphenous vein surgery: a duplex ultrasound study. *Cardiovasc Surg* 4(3): 364-367.
- Travers JP, Rhodes JE, Hardy JG & Makin GS (1993) Postoperative limb compression in reduction of haemorrhage after varicose vein surgery. *Ann R Coll Surg Engl* 75(2): 119-122.
- van Bemmelen PS, Bedford G, Beach K & Strandness DE (1989) Quantitative segmental evaluation of venous valvular reflux with duplex ultrasound scanning. *J Vasc Surg* 10: 425-431.
- van den Oever R, Hepp B, Debbaut B & Simon I (1998) Socio-economic impact of chronic venous insufficiency. *International Angiology* 3(17): 161-167.
- van der Heijden FH & Bruyninckx CM (1993) Preoperative colour-coded duplex scanning in varicose veins of the lower extremity. *Eur J Surg* 159(6-7): 329-333.
- Watts GT (1972) Endovenous diathermy destruction of internal saphenous. *Br Med J* 4(831): 53.
- Weiss RA & Weiss MA (1993a) Painful teleangiectasias: diagnosis and treatment. In: Bergan JJ & Goldman MP (eds) *Varicose veins and teleangiectasias, diagnosis and treatment*, Quality Medical Publishing Inc, St. Louis, p 389-406.
- Weiss RA & Weiss MA (1993b) Doppler ultrasound findings in reticular veins of the thigh subdermic lateral venous system and implications for sclerotherapy. *J Dermatol Surg Oncol* 19(10): 947-951.
- Weiss RA & Duffy D (1999) Clinical benefits of lightweight compression: reduction of venous-related symptoms by ready-to-wear lightweight gradient compression hosiery. *Dermatol Surg* 25(9): 701-704.

- Weiss RA & Weiss MA (1996) Ambulatory phlebectomy compared to sclerotherapy for varicose and telangiectatic veins: indications and complications. *Adv Dermatol* 11: 3-16.
- Widmer LK & Wandeler JM (1978) Leg complaints and peripheral venous disorders. In: Huber H (ed) *Peripheral venous disorders Basel III*, Hans Huber Publishers, Bern, p 34-42.
- Wills V, Moylan D & Chambers J (1998) The use of routine duplex scanning in the assessment of varicose veins. *Aust N Z J Surg* 68(1): 41-44.
- Wolf B & Brittenden J (2001) Surgical treatment of varicose veins. *J R Coll Surg Edinb* 46(3): 154-158.
- Yamaki T, Nozaki M & Sasaki K (2001) Preliminary report of a new approach to sparing the greater saphenous vein for grafting: valvuloplasty combined with axial transposition of a competent tributary vein. *J Endovasc Ther* 8(2): 188-196.
- Zamboni P, Marcellino MG, Cappelli M, Feo CV, Bresadola V, Vasquez G & Liboni A (1998) Saphenous vein sparing surgery: principles, techniques and results. *J Cardiovasc Surg (Torino)* 39(2): 151-162.